

Pediatric and Adolescent Patellar Instability

Ryan Koehler

Sports Medicine Conference

5/3/24

Disclosure

- None relevant to this talk



Outline

- Background and anatomy
- Risk factors
- Imaging
- Surgical treatment options
- Case examples



Background

- Commonly seen in children and adolescents
 - 43 per 100,000
- 31% of patients presenting with acute effusion
 - Most common cause age 10-14
- Types
 - Traumatic
 - **Fixed**
 - **Obligatory**
 - Syndromic



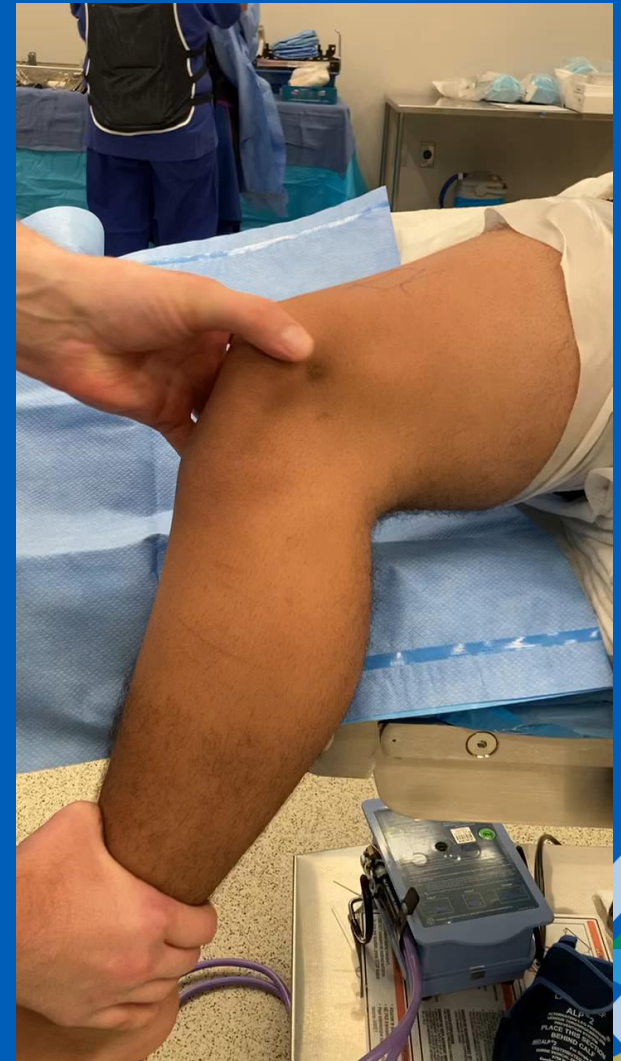Factors Contributing to Instability

- Trochlear dysplasia
- Patella alta
- Valgus alignment
- Excessive IR femur (anteversion) or ER tibia (miserable malalignment syndrome)

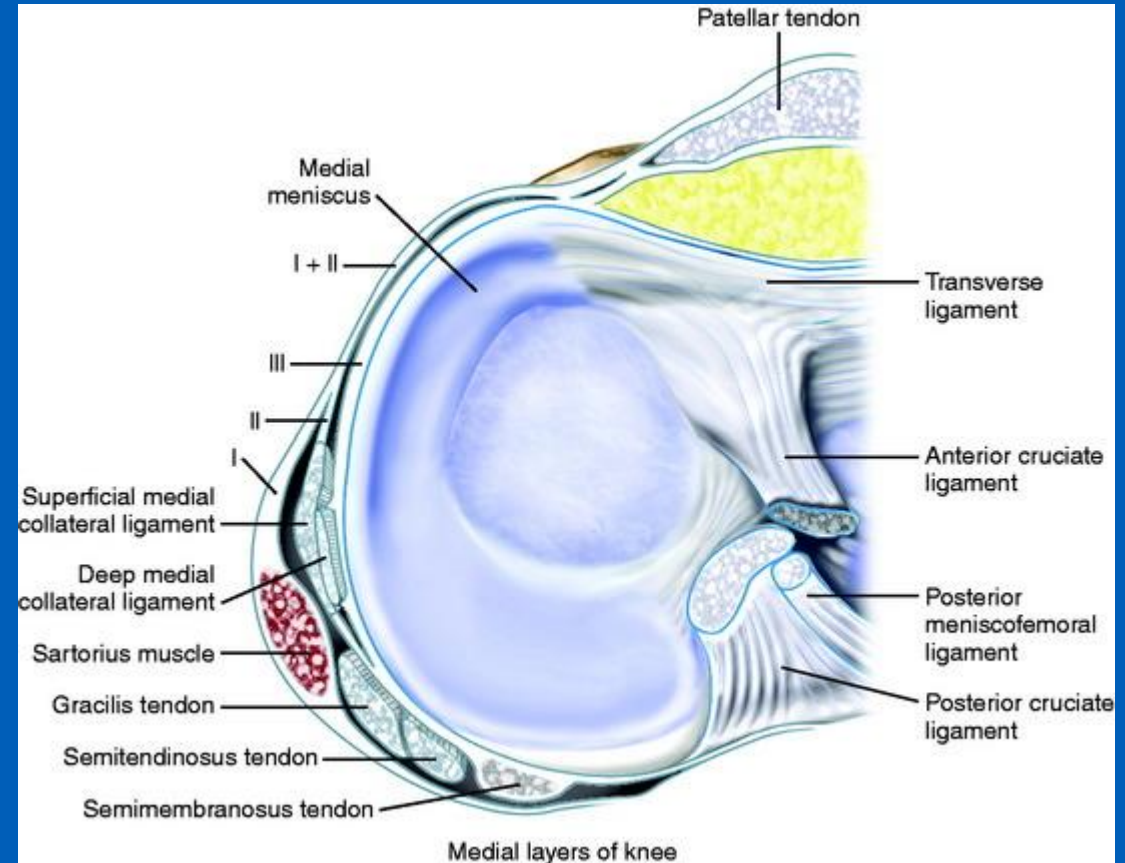
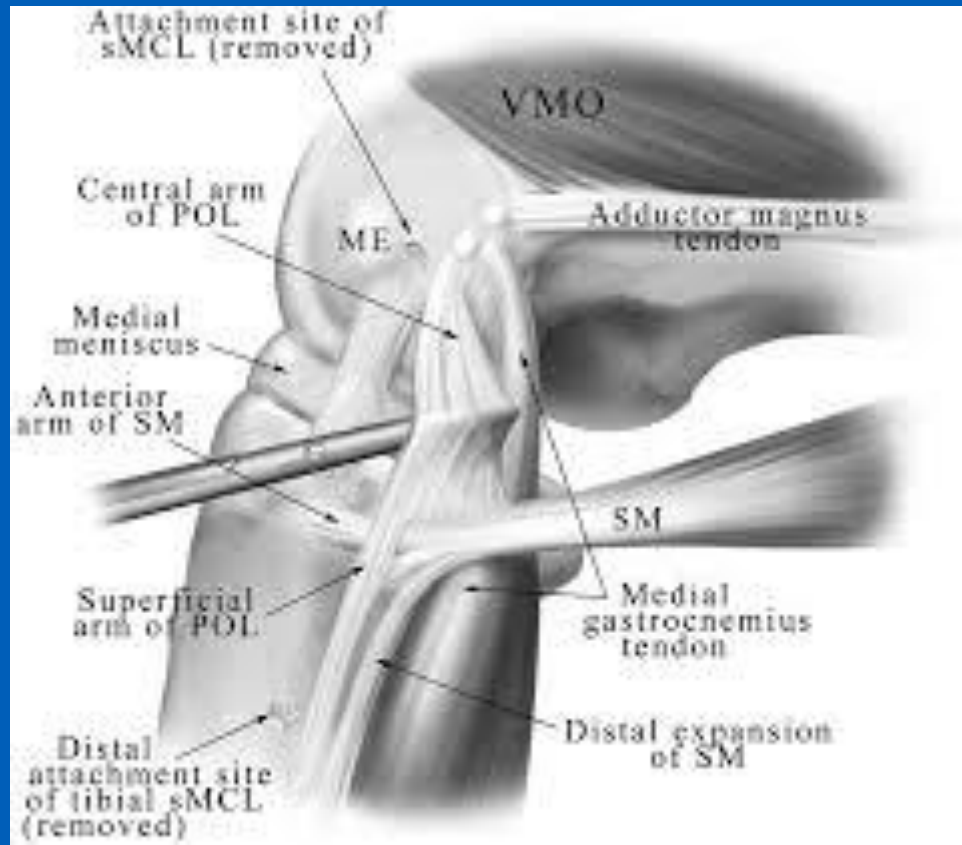


Clinical Evaluation

- Need to determine acute from chronic dislocation
 - Acute often sports related and may require reduction
 - Chronic with ADLs with self reduction
- Evaluate for hyperlaxity (Beighton test)
- J-sign indicates a supratrochlear spur is present
- Evaluate for apprehension and lateral glide
 - 1 quadrant is $\frac{1}{4}$ patellar width, 4 is a dislocation
- Evaluate medial patella and lateral femoral condyle
 - 30-40% have osteochondral fracture

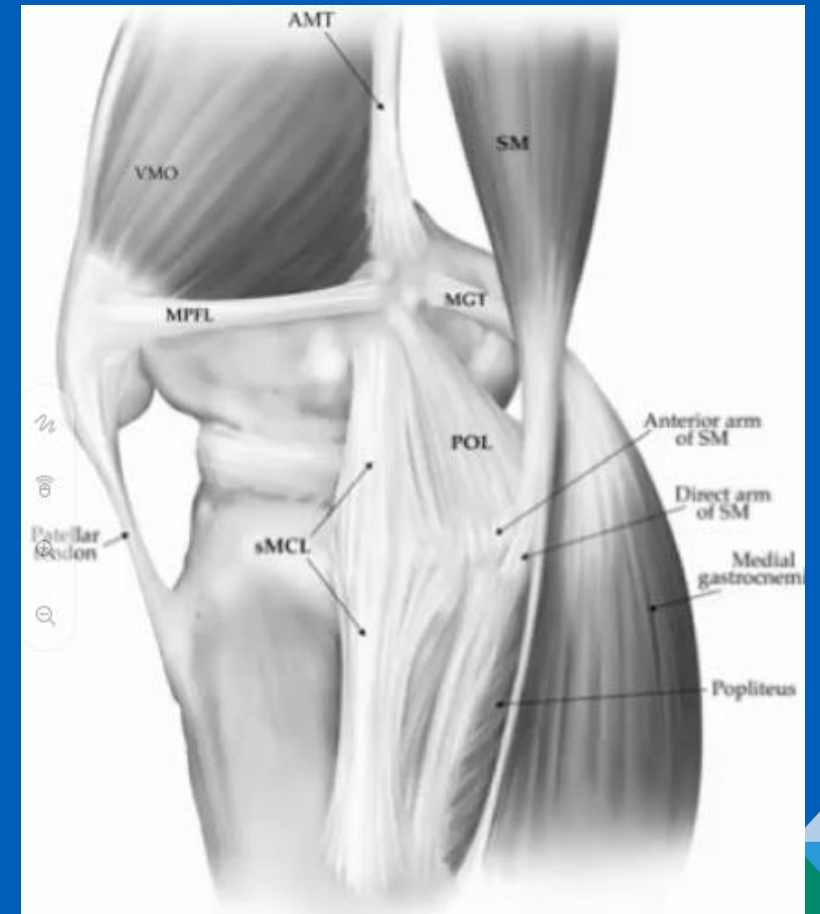


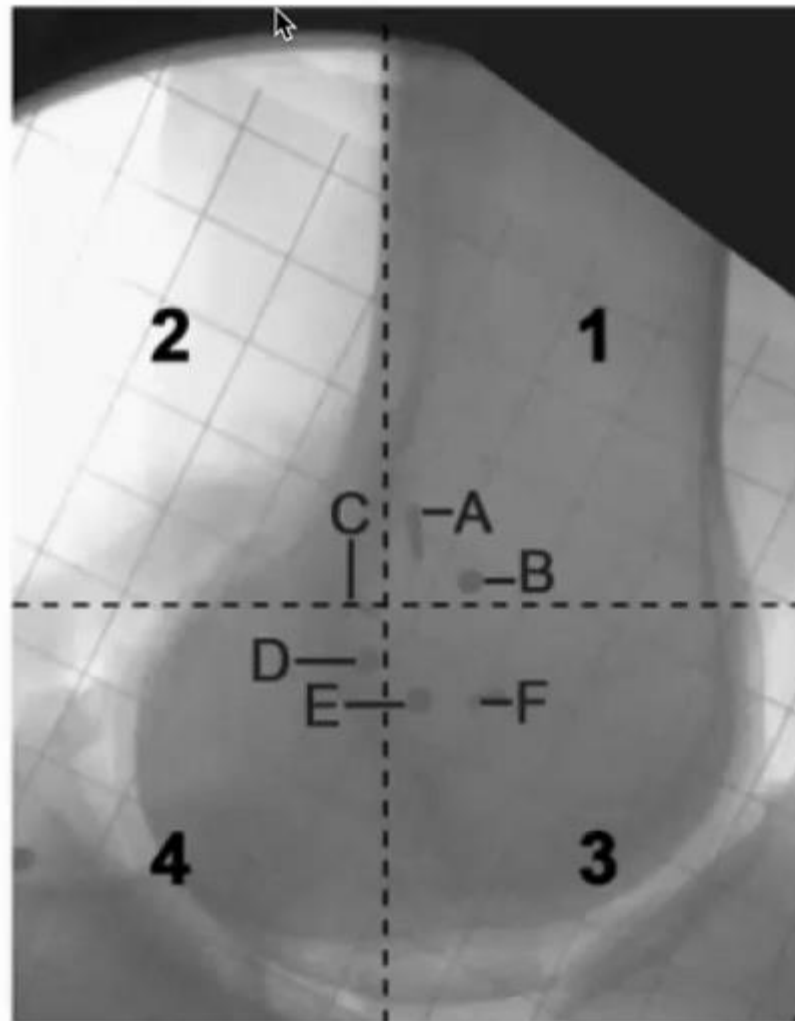
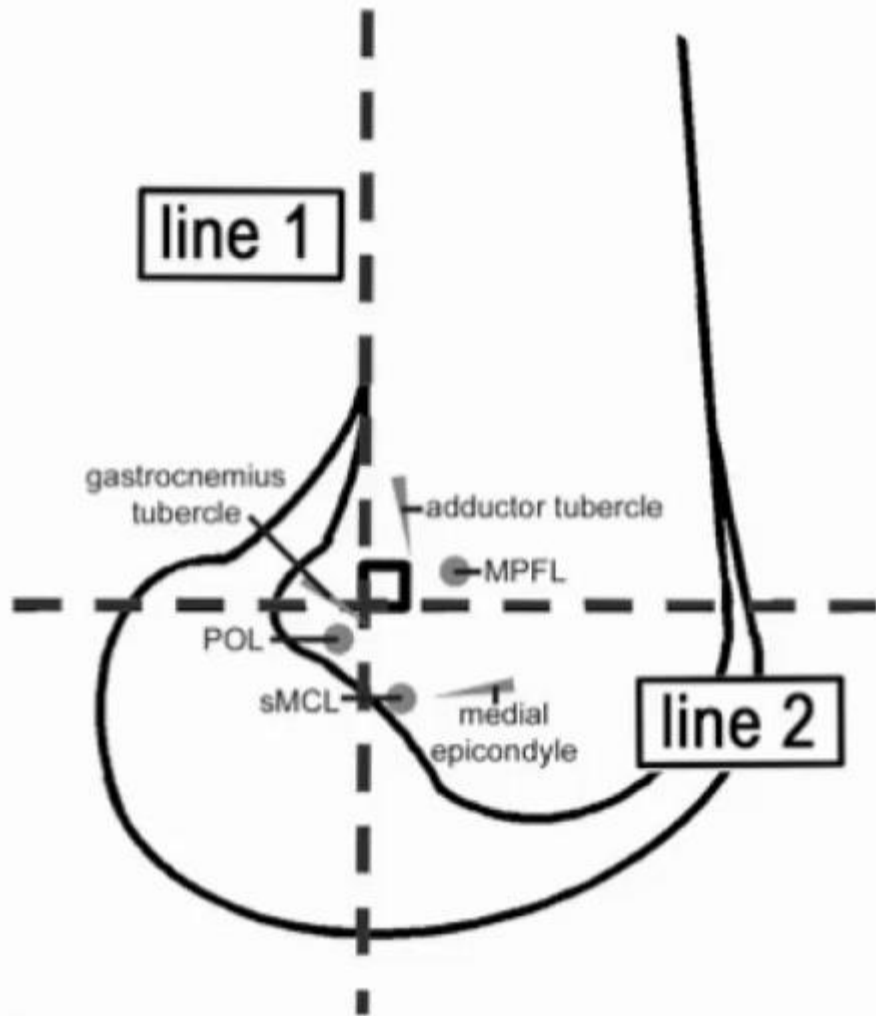
Medial Knee Anatomy



MPFL

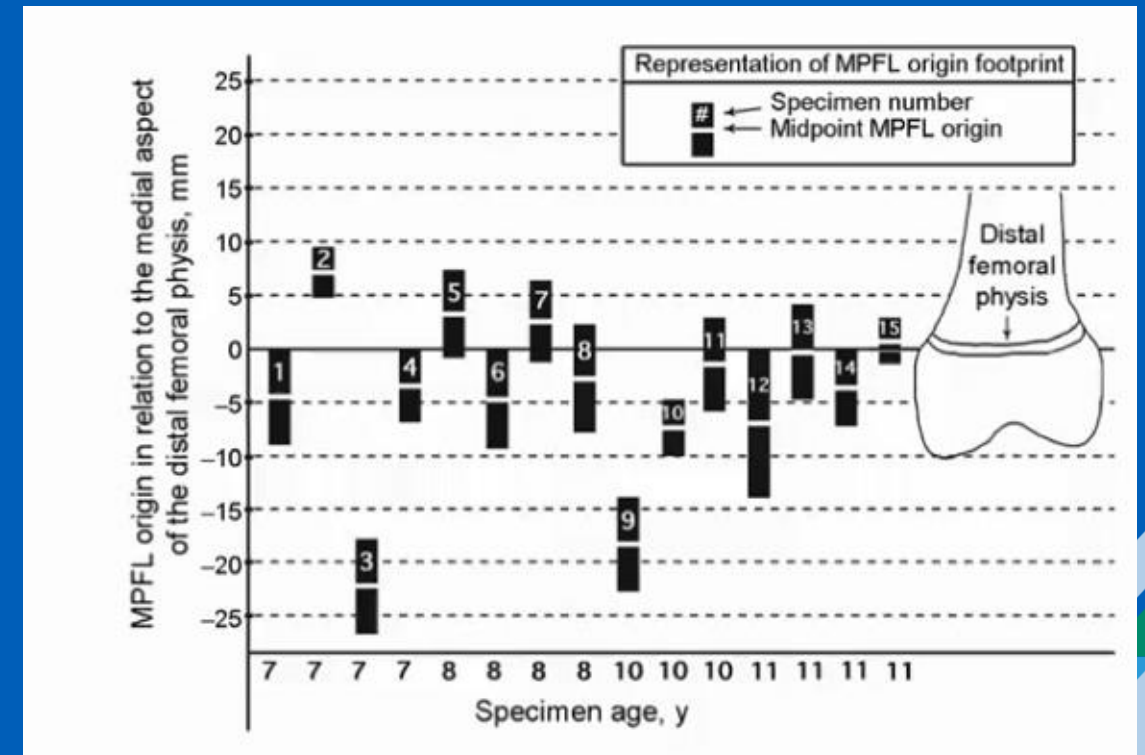
- Damaged in 78-94% of patellar dislocations
- Femoral origin is just anterior and distal to adductor tubercle
- Patellar insertion 1cm distal to superior pole
 - upper 1/3 of patella
- Inferior straight bundle and superior oblique bundle
- 55mm long and 15mm wide





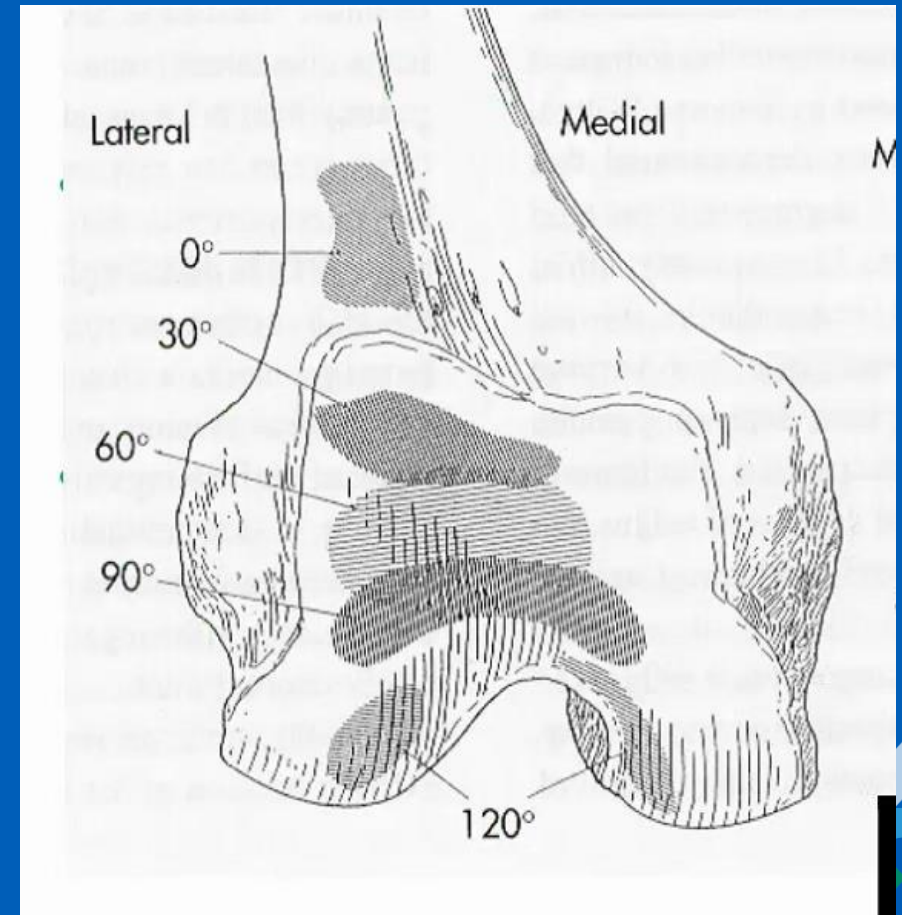
Pediatric MPFL

- Variable femoral insertion relative to the physis
 - Range from 7.5mm proximal to 16mm distal
- **MOST commonly found DISTAL to physis (86%)**
 - 5mm distal on average
 - Variable with age

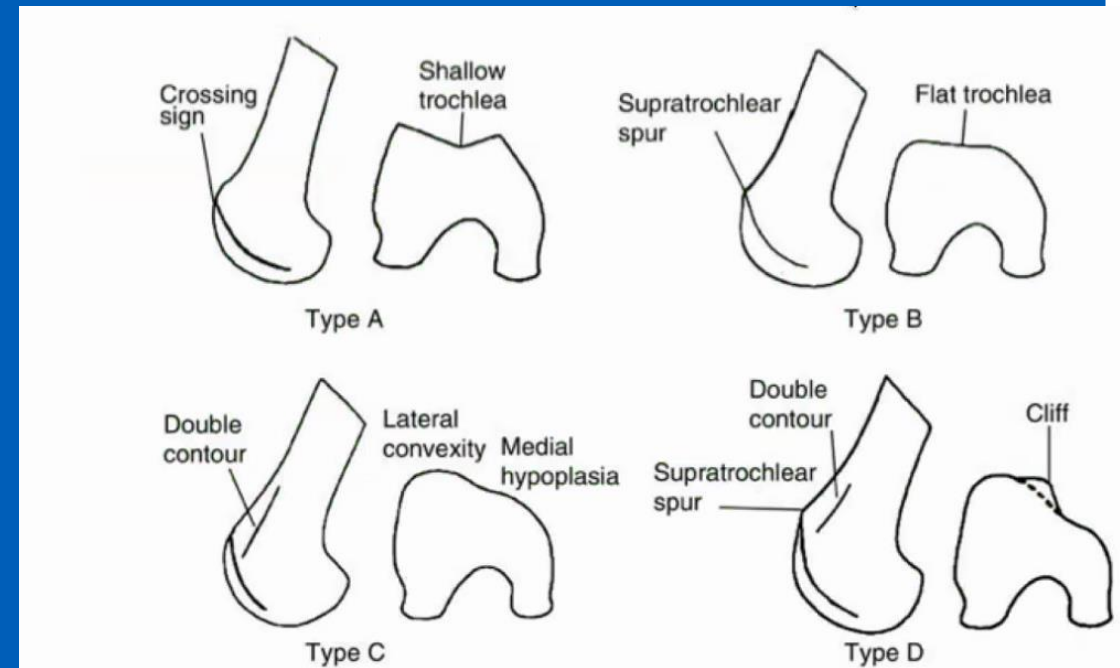
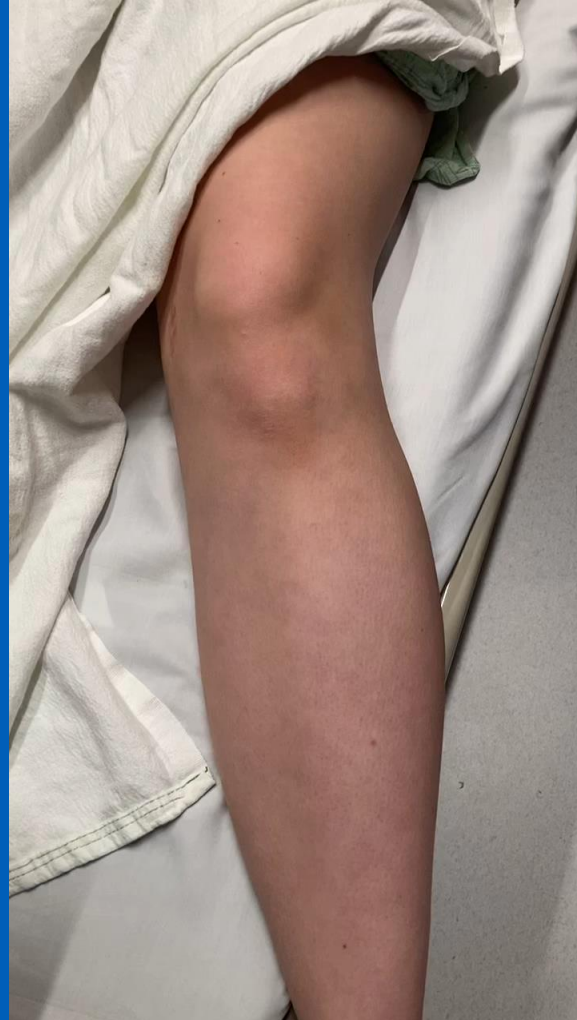
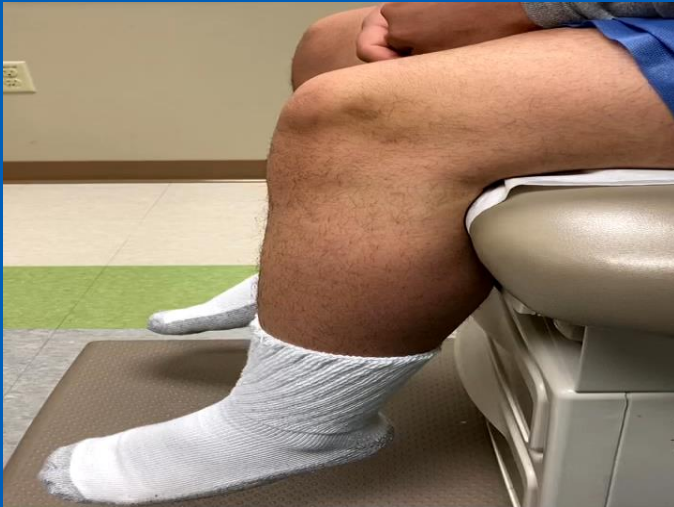
Joint Geometry

- Lateral facet
 - Adds constraint in extension and early flexion
- Medial facet
 - Not fully engaged until 20-30 degrees of flexion
- Trochlea
 - Full extension is high risk as soft tissue constraints do most work
 - Contact area moves during flexion
 - Beyond 120 degrees of flexion the femoral condyles are restraints

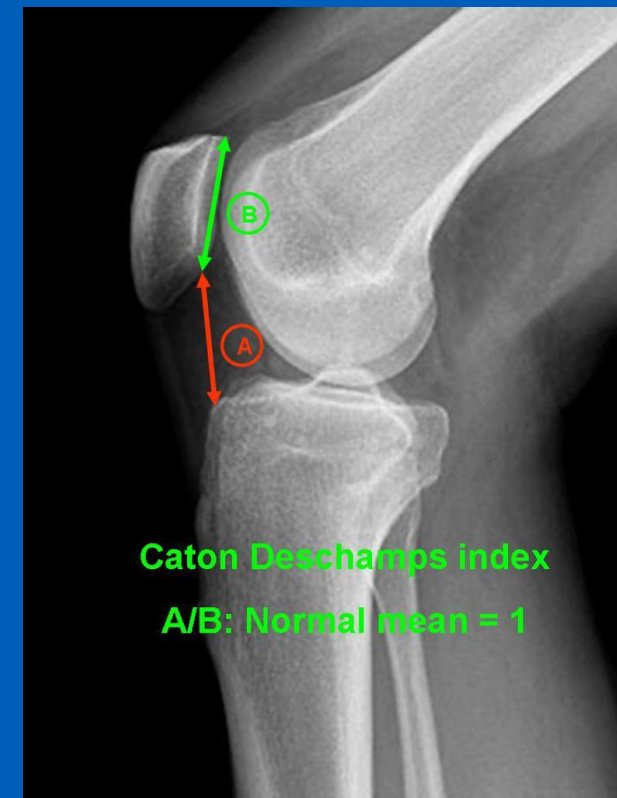


Trochlear Dysplasia



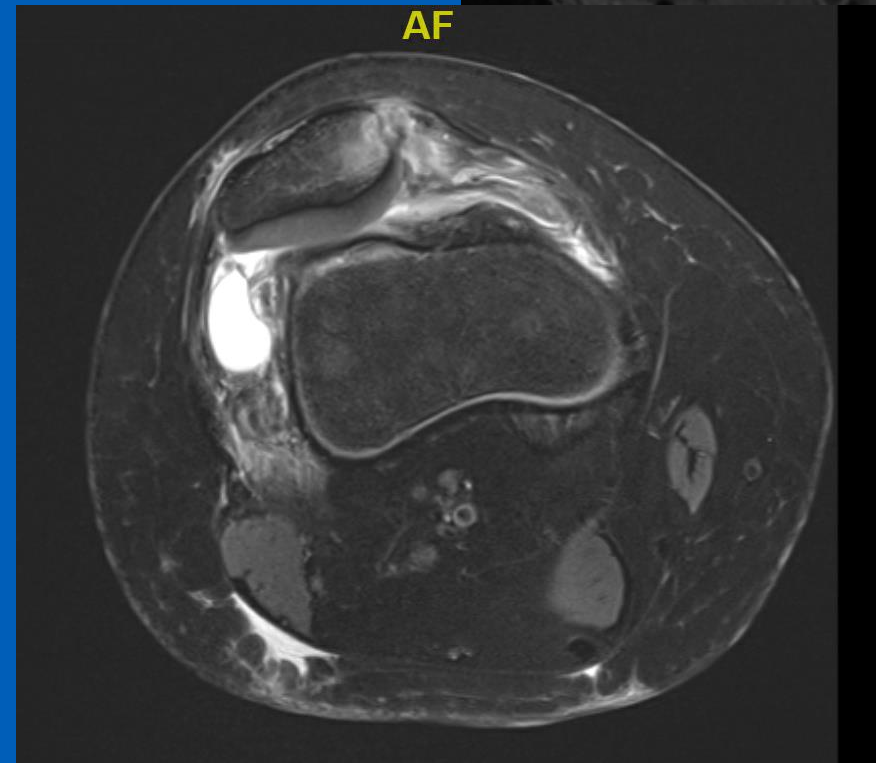
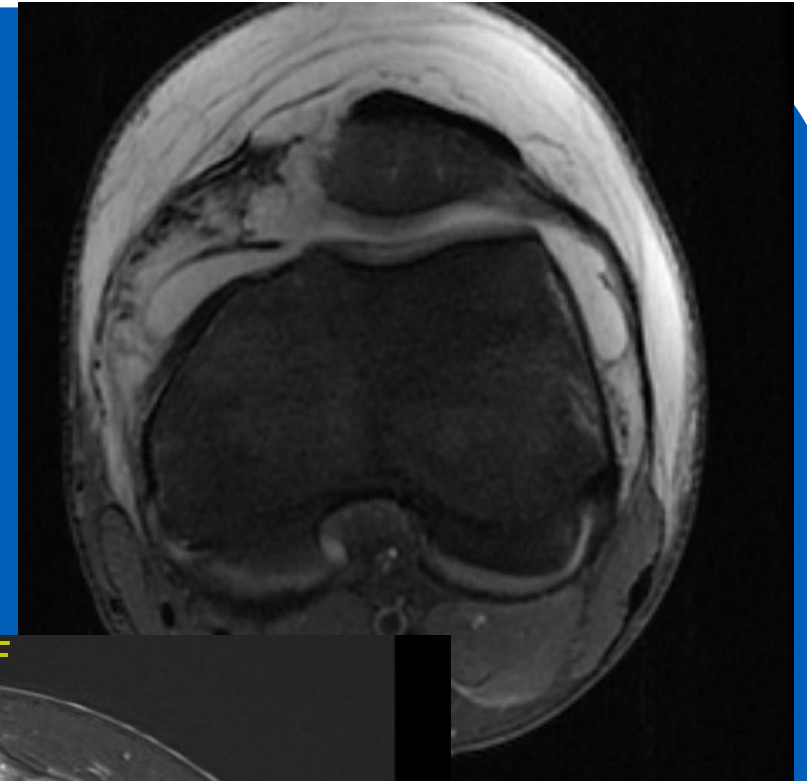
Radiographs

- AP/Lateral(30 degrees Flexion)/Merchant Views/Notch
- Osteochondral fractures (50% seen on xray)
- Status of physis
- Patella Alta
 - Canton-Deschamps (1-1.2 normal)
- Trochlear dysplasia
 - Dejour classification

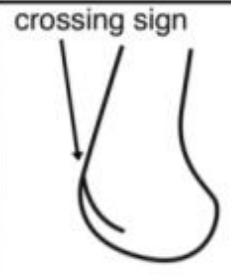

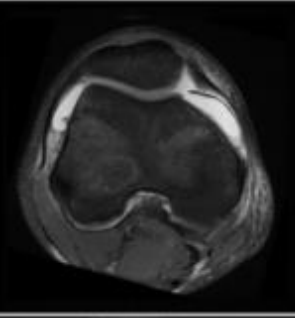



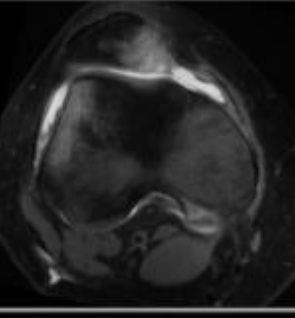



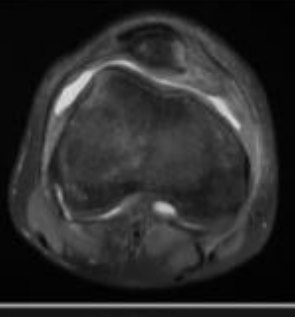



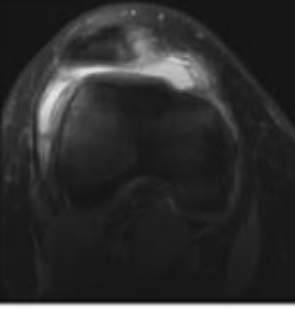



MRI

- Not needed on every dislocation
 - Osteochondral fragment on xray
 - Large effusion
 - Multiple dislocations
- Better to evaluate
 - Trochlear dysplasia
 - MPFL injury
 - OC fracture
 - TT-TG



Dejour

	Radiographic Dejour	MRI Dejour	
Type A	<p>crossing sign</p>  		<p>shallow trochlea >145°</p> 
Type B	<p>supra trochlear spur</p>  		<p>flat trochlea</p> 
Type C	<p>double contour</p>  		<p>lateral convexity medial hypoplasia</p> 
Type D	<p>double contour</p> <p>supra trochlear spur</p>  		<p>cliff</p> 



First Time Dislocation

- Recurrent dislocation in 30-40%
- Higher risk with:
 - Open physis (Age 11-13)
 - Trochlear dysplasia
- Brace: Knee immobilizer with quick transition to J brace or True Pull brace
- Rehab, Rehab, Rehab
 - Improve poor mechanics focused on knee and hip
 - Dynamic valgus with single leg squat
- Surgery for loose body removal or OC fracture fixation



Recurrent Dislocations

- Evaluate limb mechanical axis
 - Standing alignment
 - Pelvic obliquity and LLD
 - Foot progression angle
- Evaluate femoral version and tibial torsion
 - Miserable malalignment syndrome
- Lateral glide
 - 1 = $\frac{1}{4}$ patella width, 4 = subluxation or dislocation
- Apprehension sign
- Obvious J-sign or jumping J-sign



Patellar Stabilization Options

- Medial retinacular repair or medial imbrication only
- Medial patellar ligament reconstruction
 - **MPFL**
 - MPTL
 - MQTFL
- Lateral release or lengthening +/- Quad lengthening
- Distal patellar tendon realignment
 - TTO or soft tissue procedure
- Trochleoplasty



« Menu à la Carte »

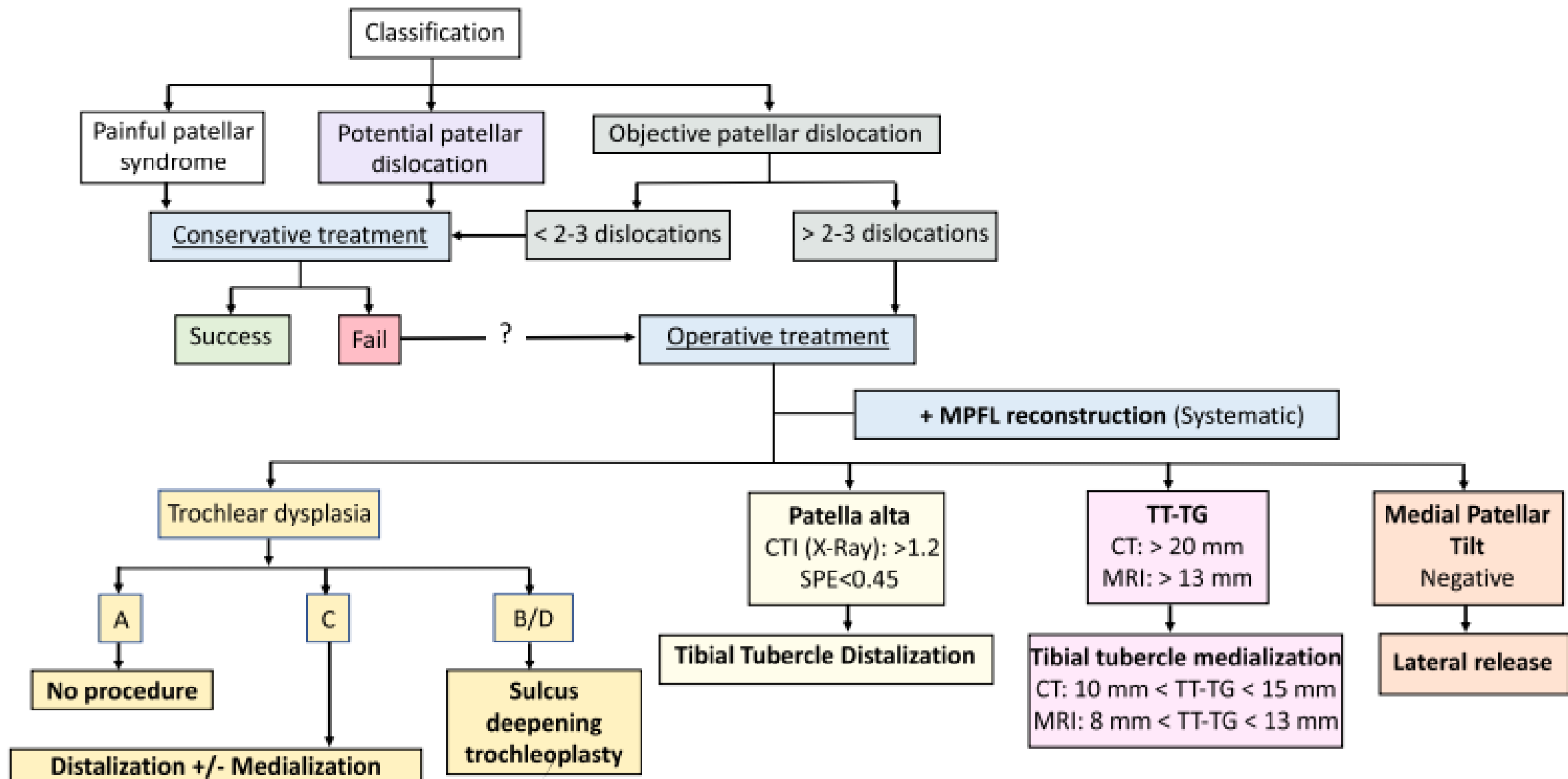
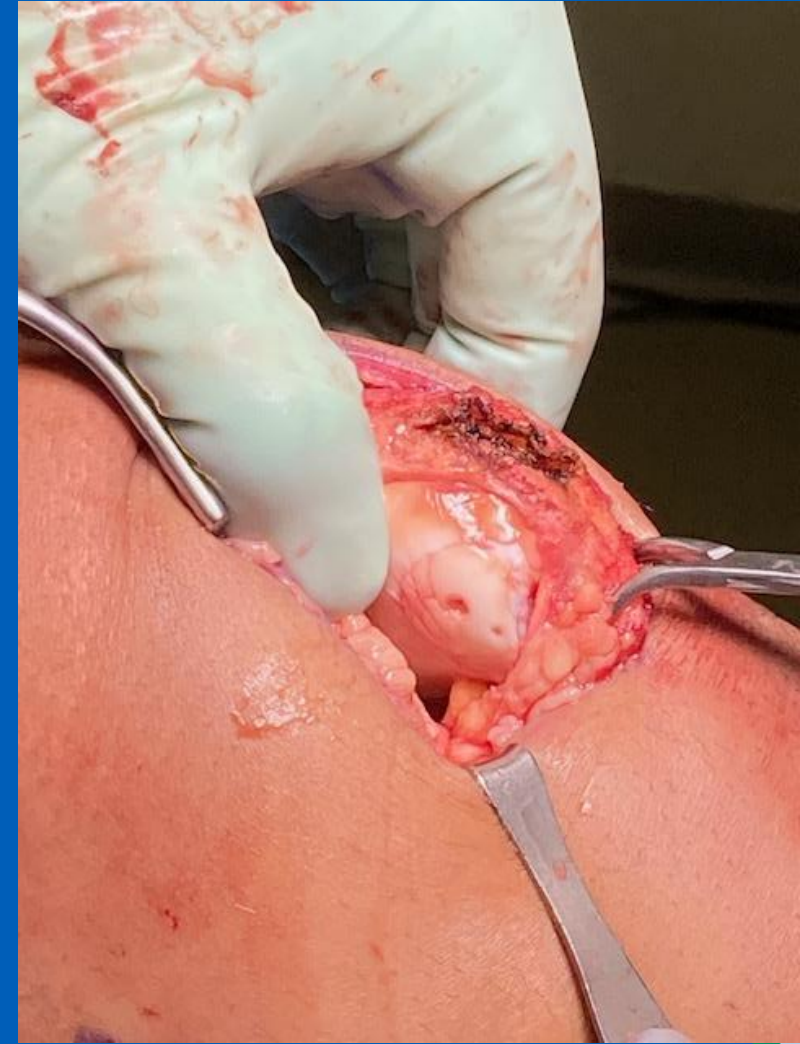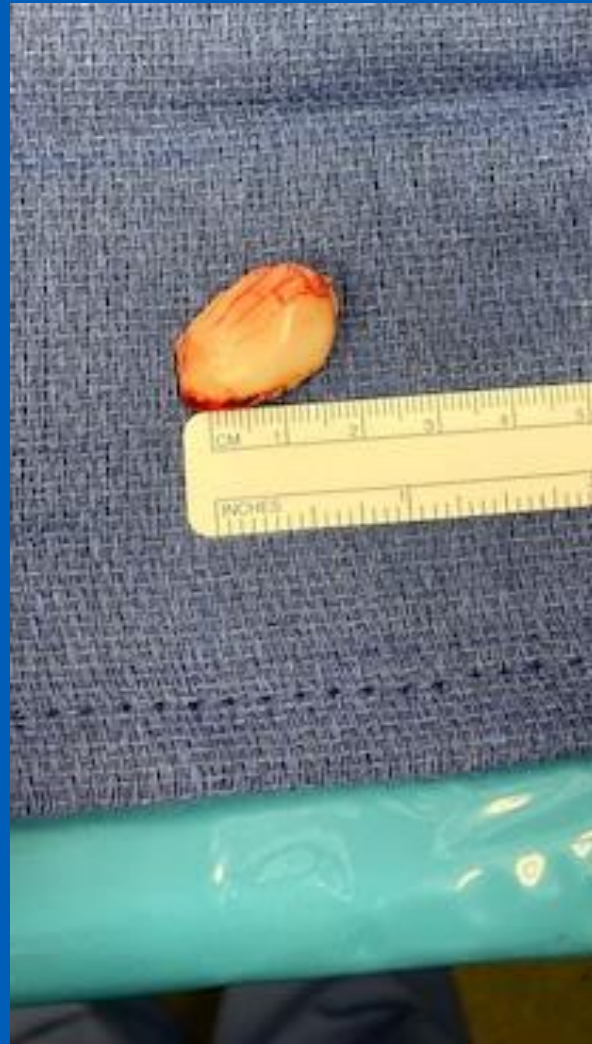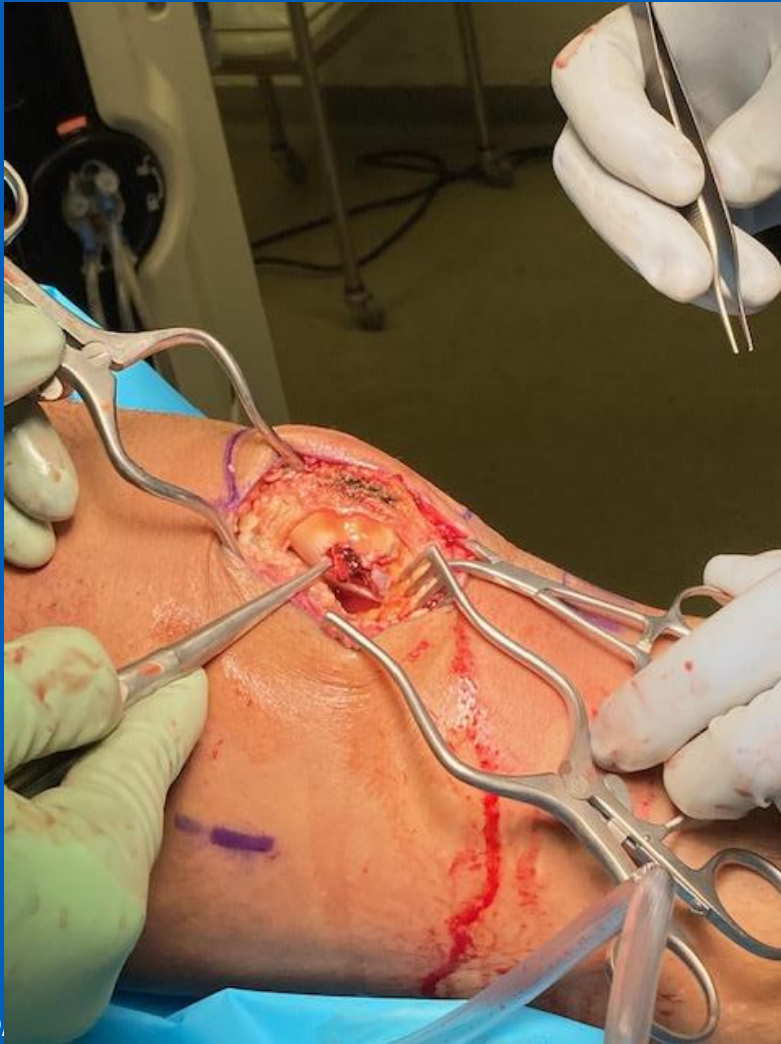


Fig. 5 The updated treatment algorithm for patellar instability. Each abnormality has to be evaluated and surgically corrected when indicated ("menu à la carte")

Osteochondral Fractures



MPFL Reconstruction

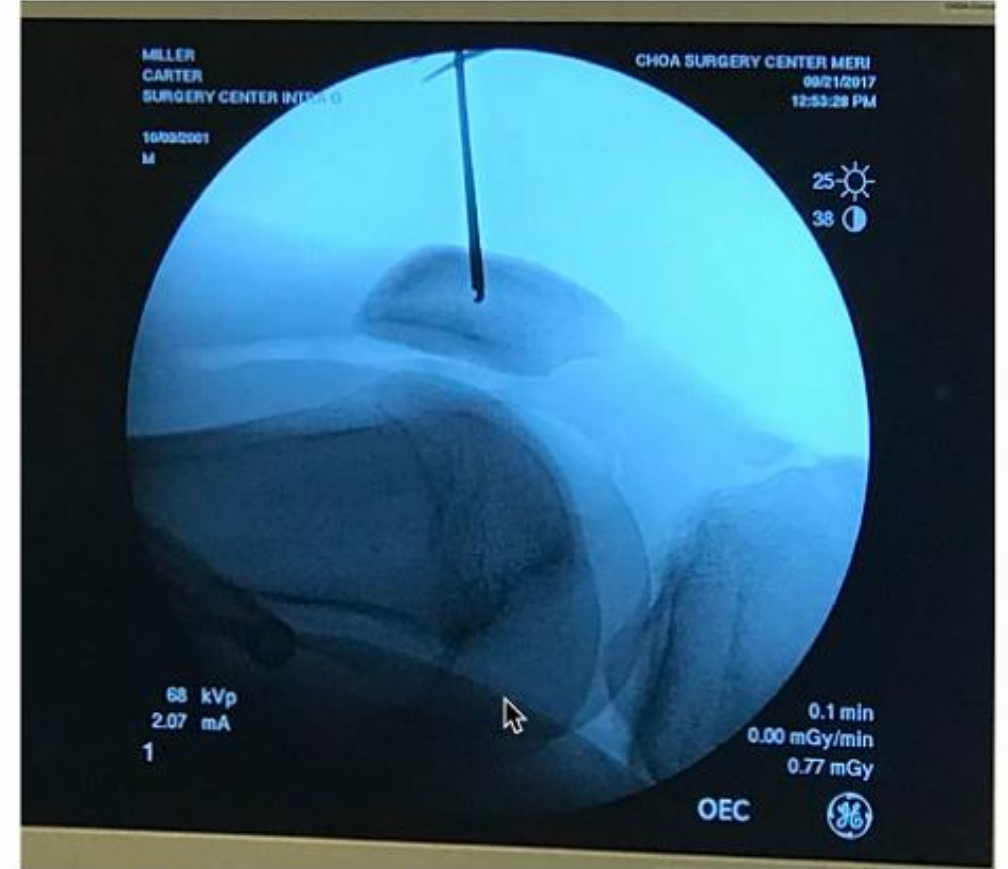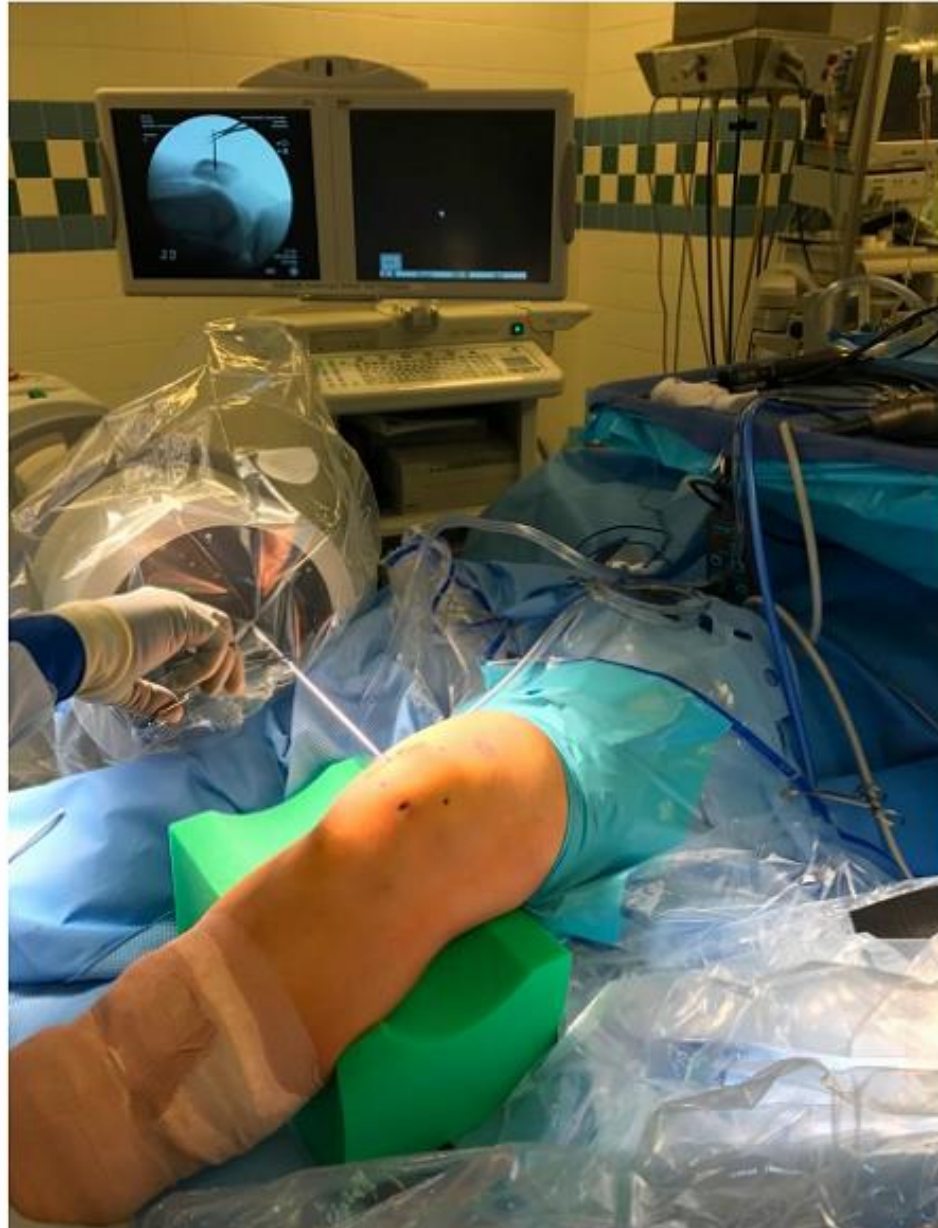
- Goal is to restore normal checkrein of the medial patella
 - Full extension to 30 degrees of flexion
- Lots of options for graft
 - Autograft (Hamstring, quad, patella)
 - Allograft
- **No major difference has been shown between allograft and autograft**



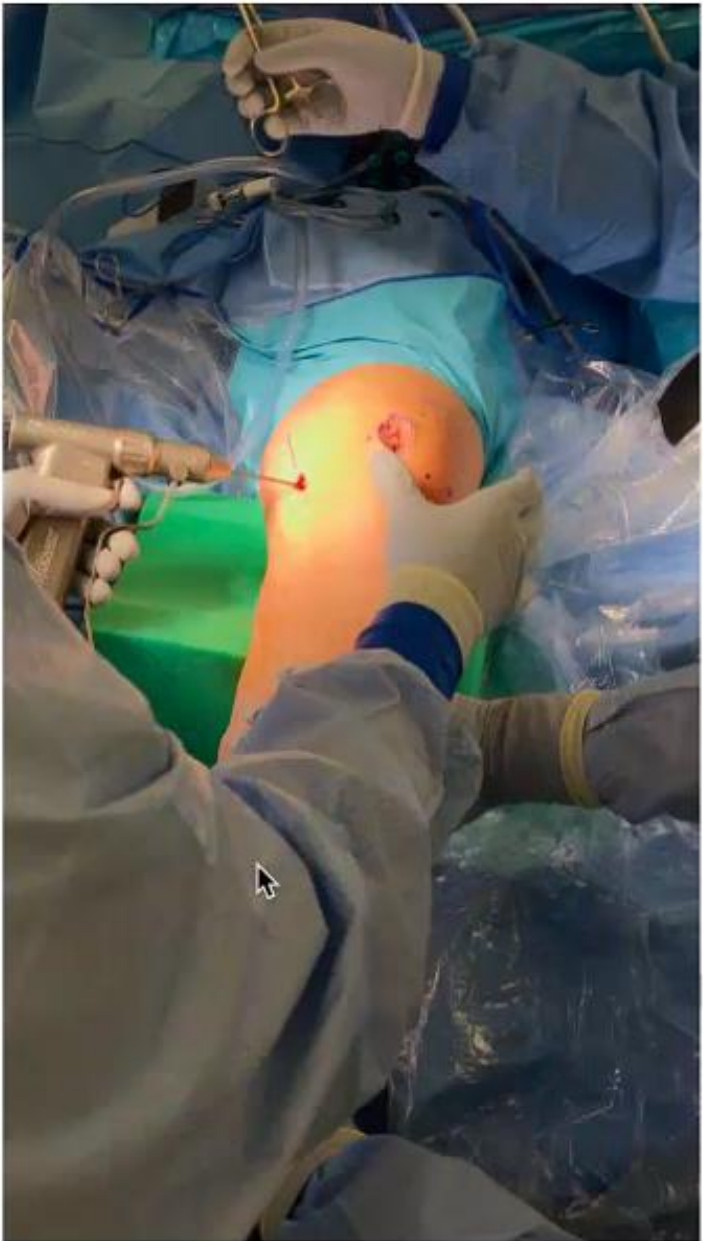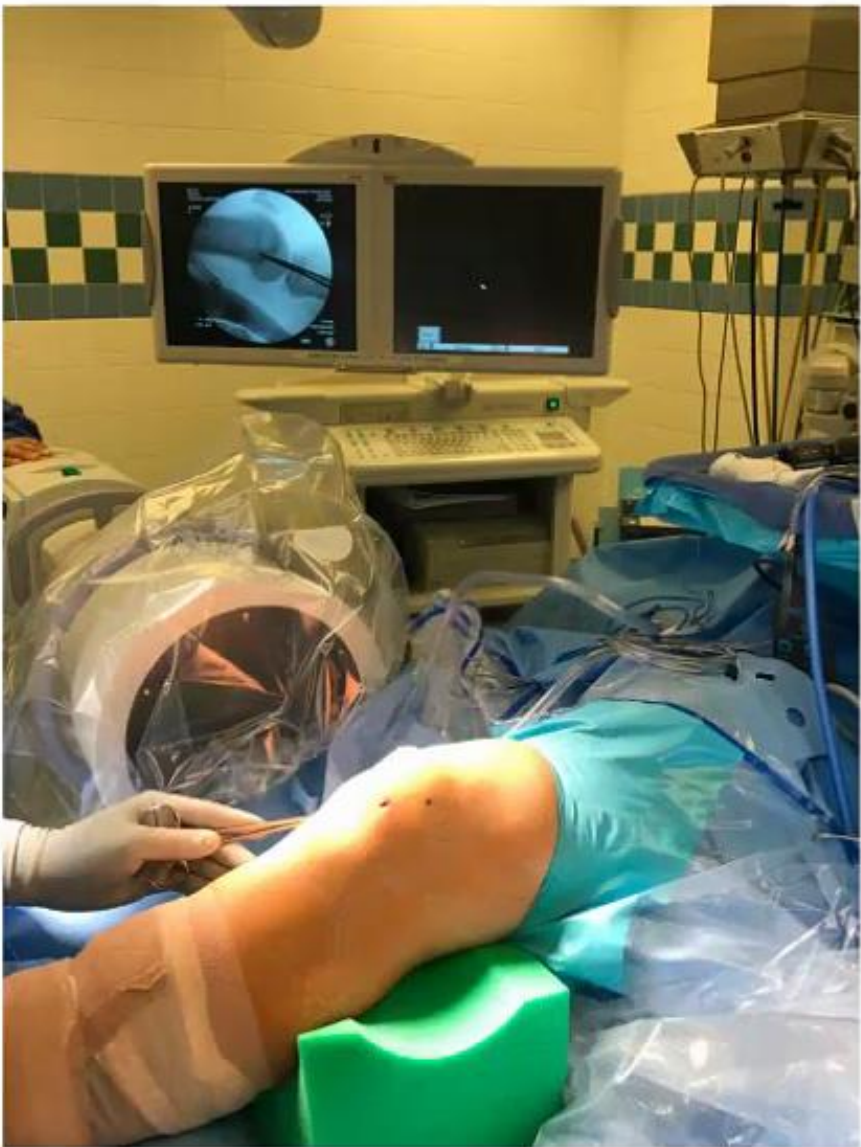MPFL Sequence

- EUA
- Graft prep (gracillis allograft)
- Patella exposure
- Drill patella tunnel
- Develop plane between layers 2-3 to adductor tubercle
- Lateral fluoro to ID Schottle's point
- Ream femoral tunnel
- Fix graft in patella
- Pass graft between layers 2-3
- Tension and fix graft in femur

Ream Patella Socket

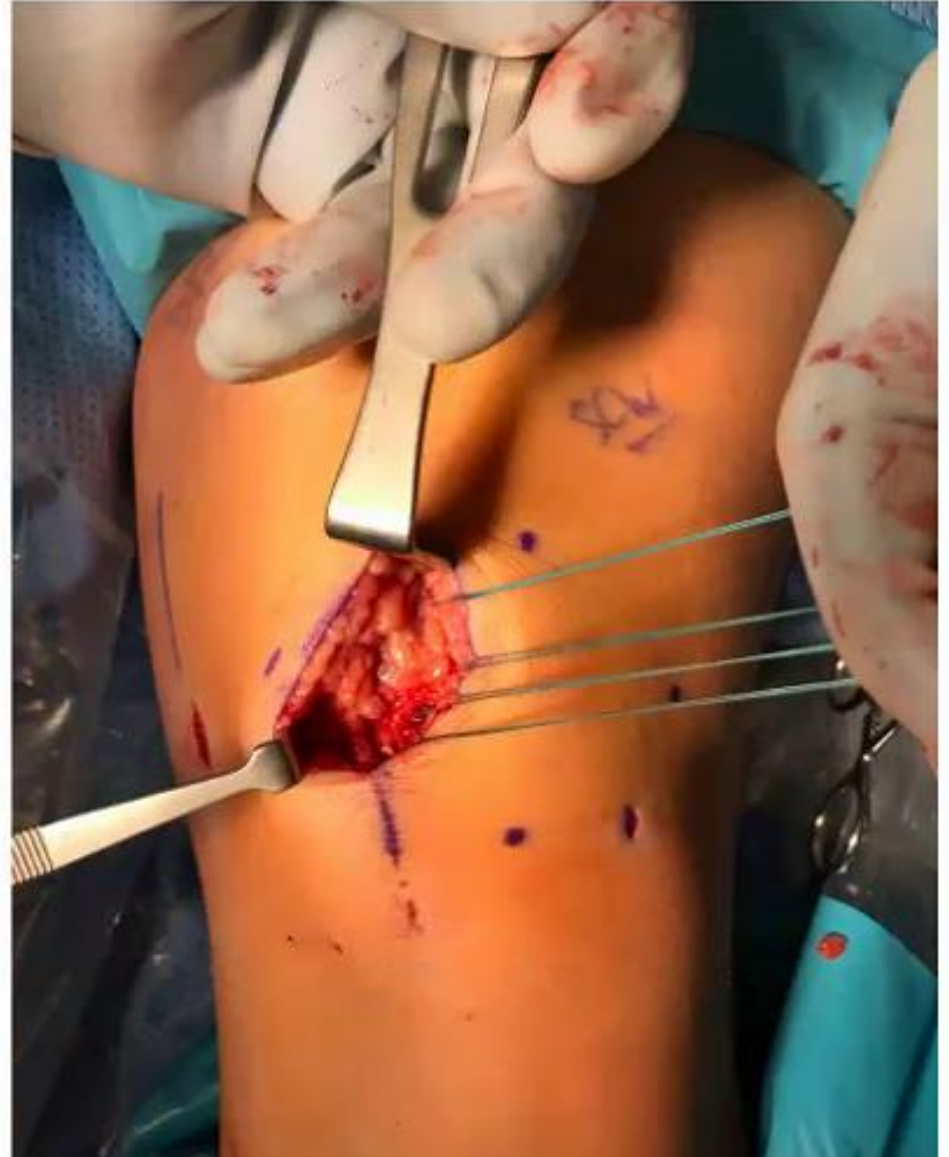


Schottle's Point



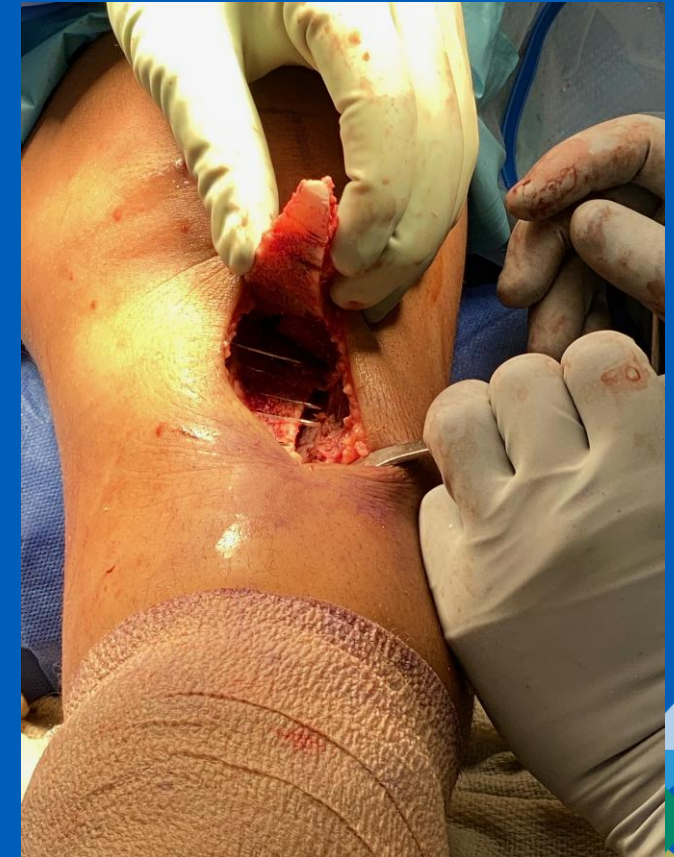Medial Imbrication

- Included as a portion of closure
- Incorporates
 - VMO
 - MPFL
 - MPTL

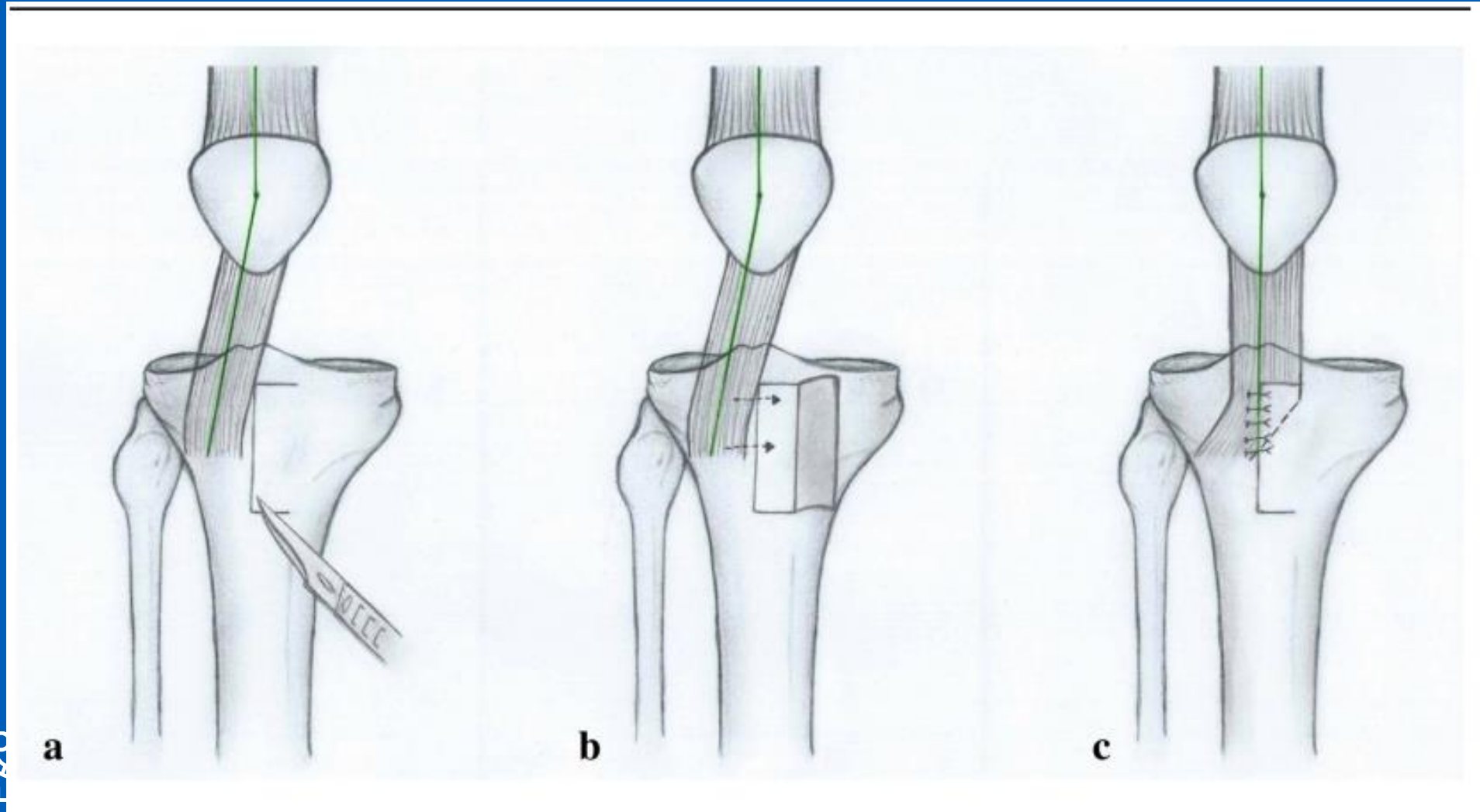


Tibial Tubercle Osteotomy

- Skeletally maturing patients
- Can use for medial and distal translation
 - Correct TT-TG to around 10
 - Correct CDI to around 1
- Can angle cut to get anterior translation
 - Offload patellar cartilage injury
- Place k wires as cutting block and cut with saw
- Osteotome to mobilize leaving distal part intact unless doing distalization
- Fix with 4.5mm fully threaded screws

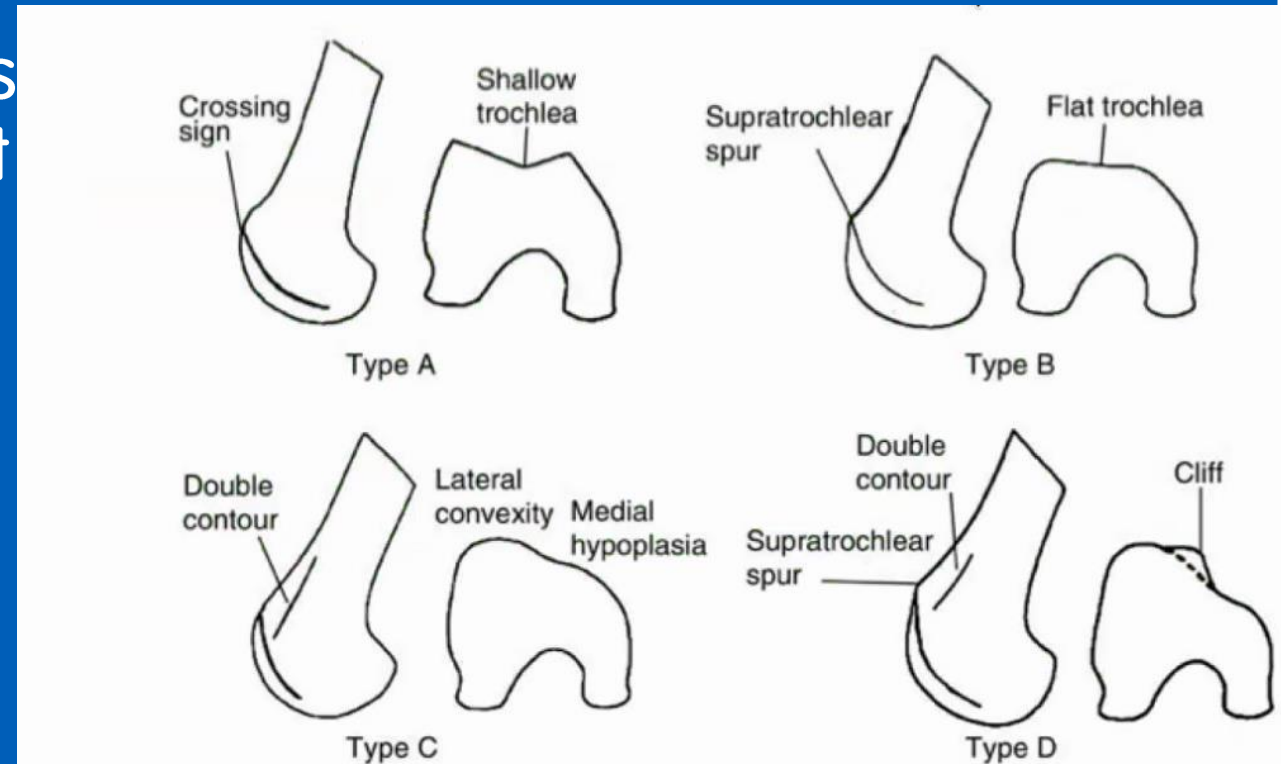


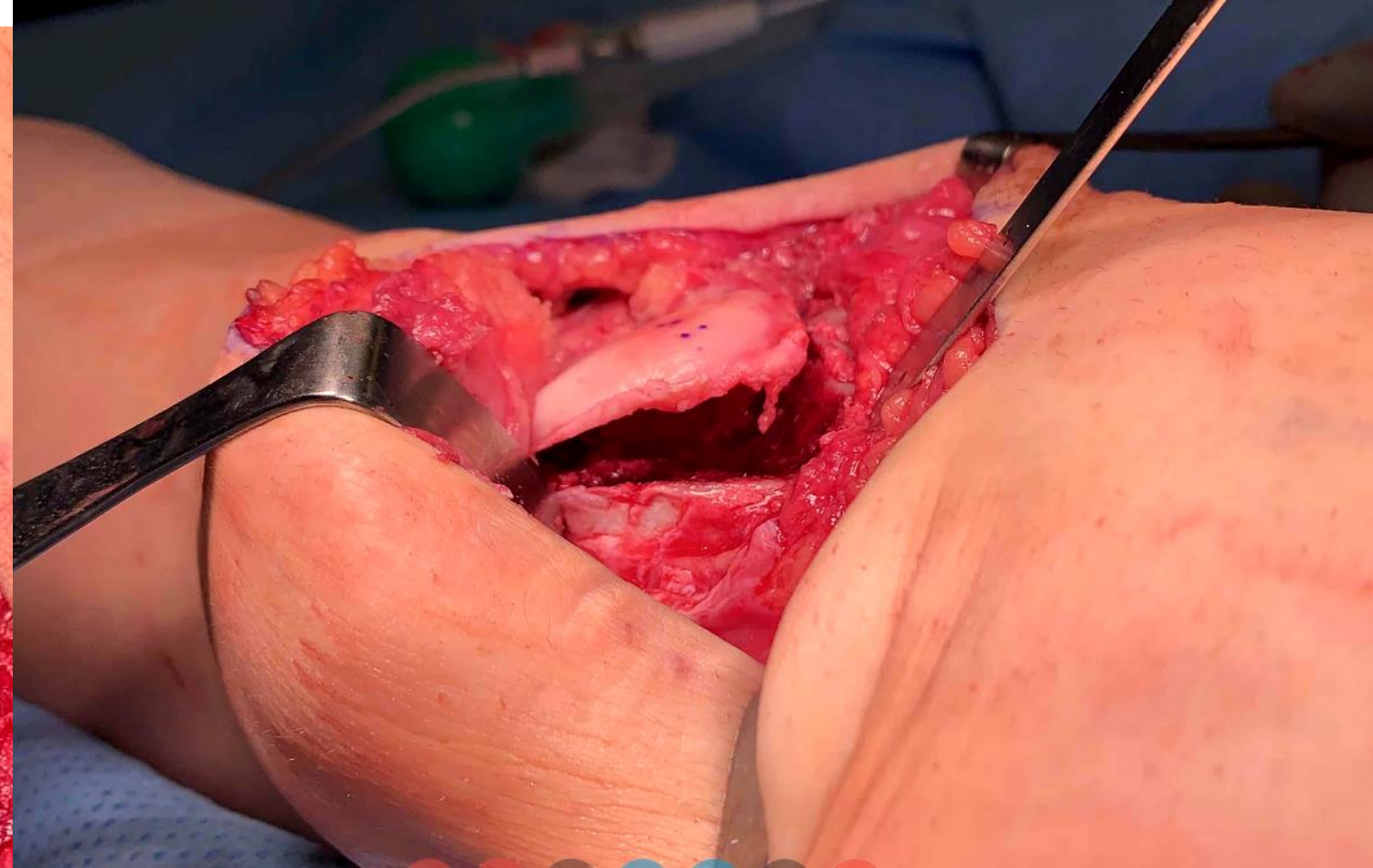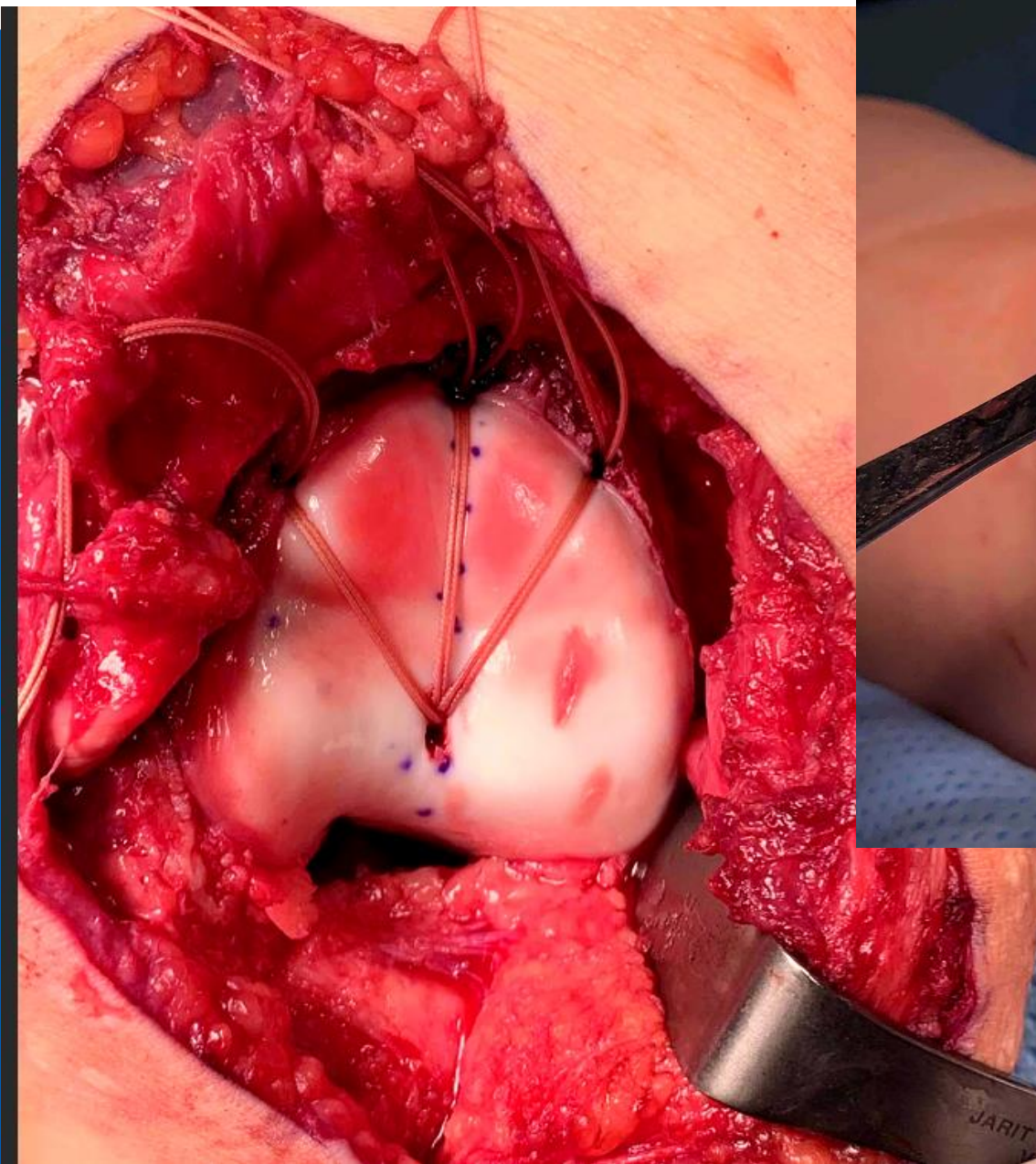
Distal Patellar Ligament Realignment

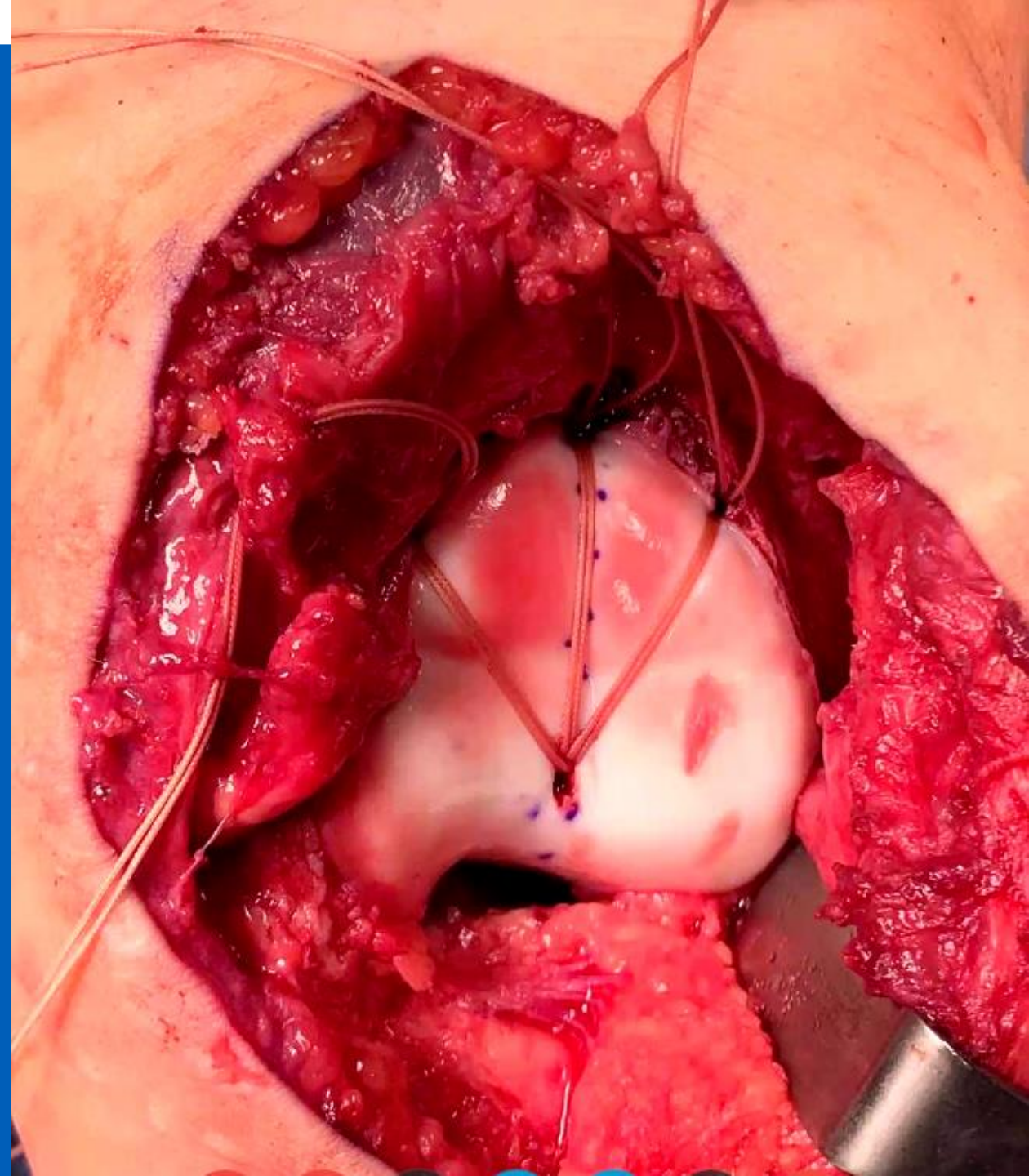
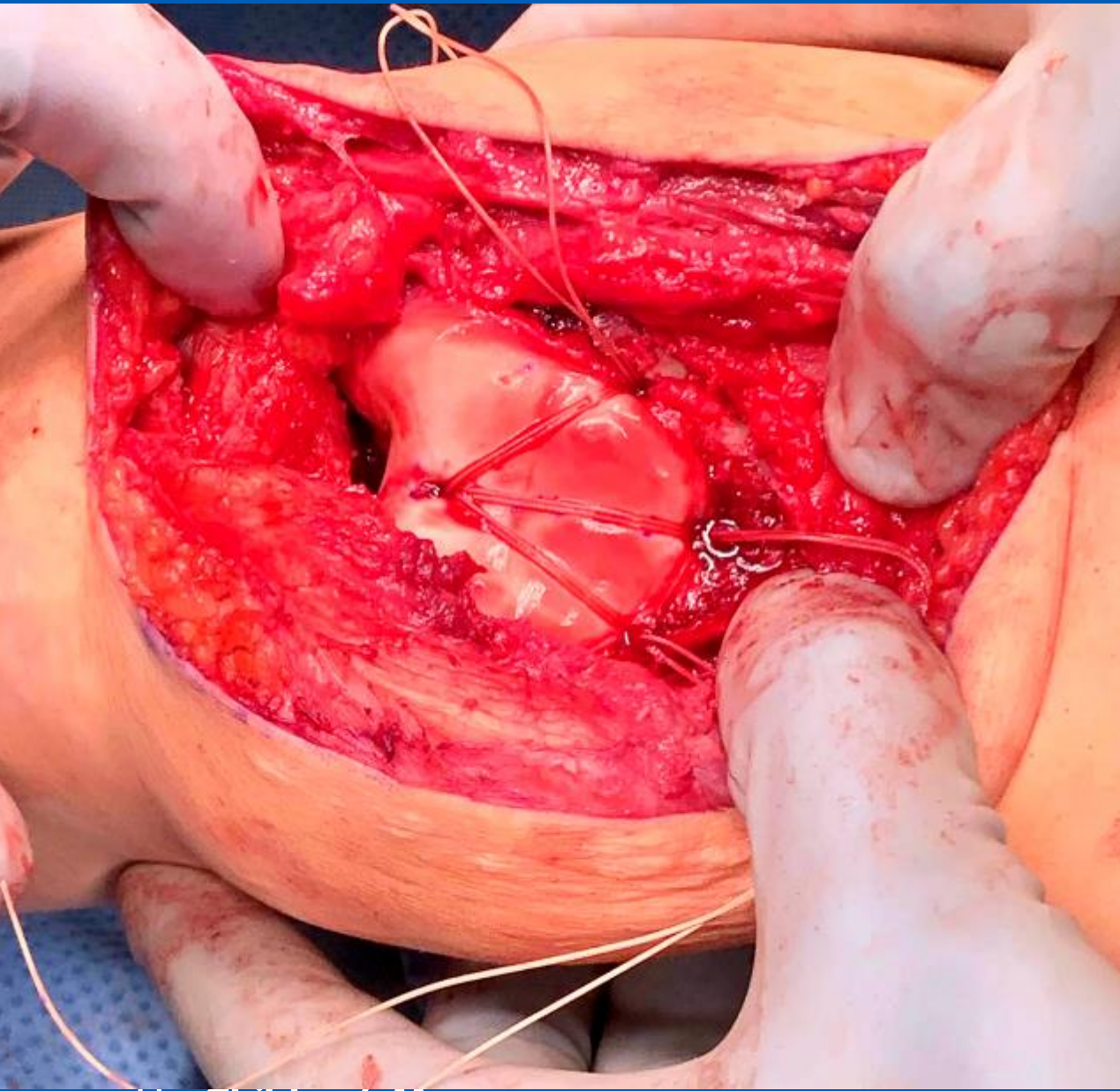


Trochleoplasty

- Several opinions on when to add this
- DeJour B and D dysplasia
- Removal of the supratrochlear spur seems to be the biggest benefit
- Thin and thick flap techniques







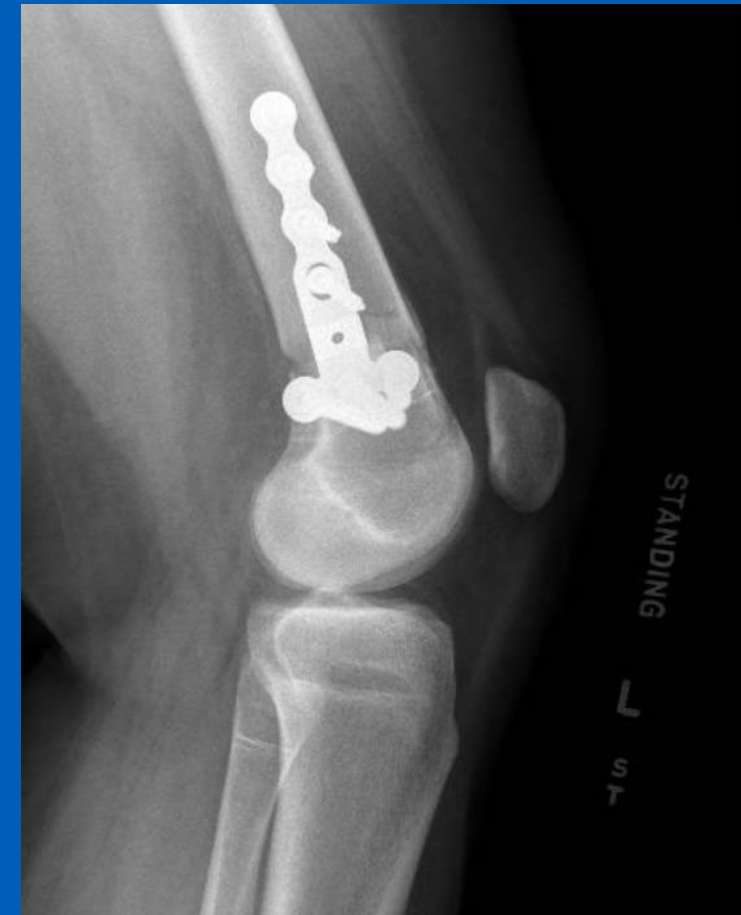Other Patellar Stabilizing Procedures

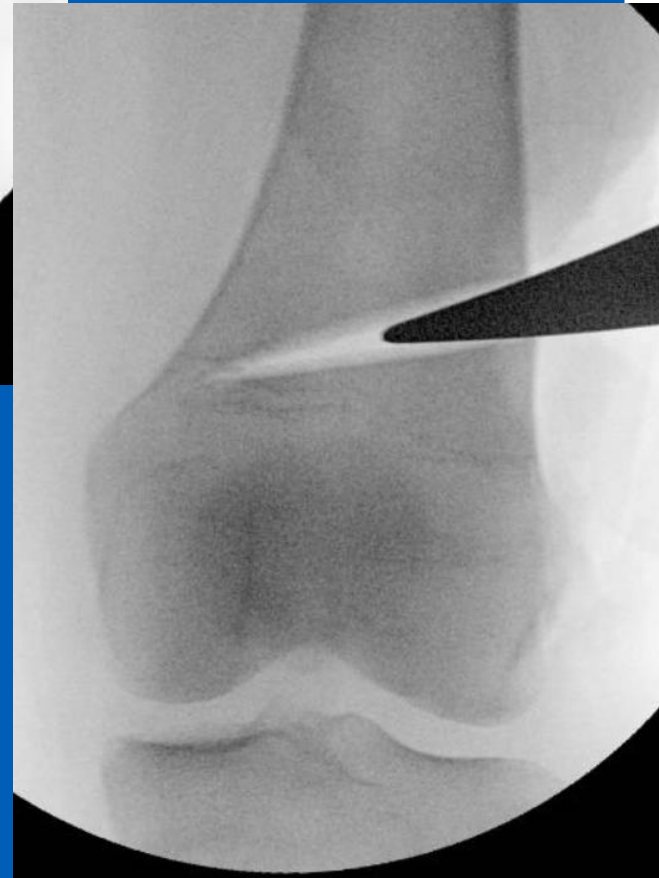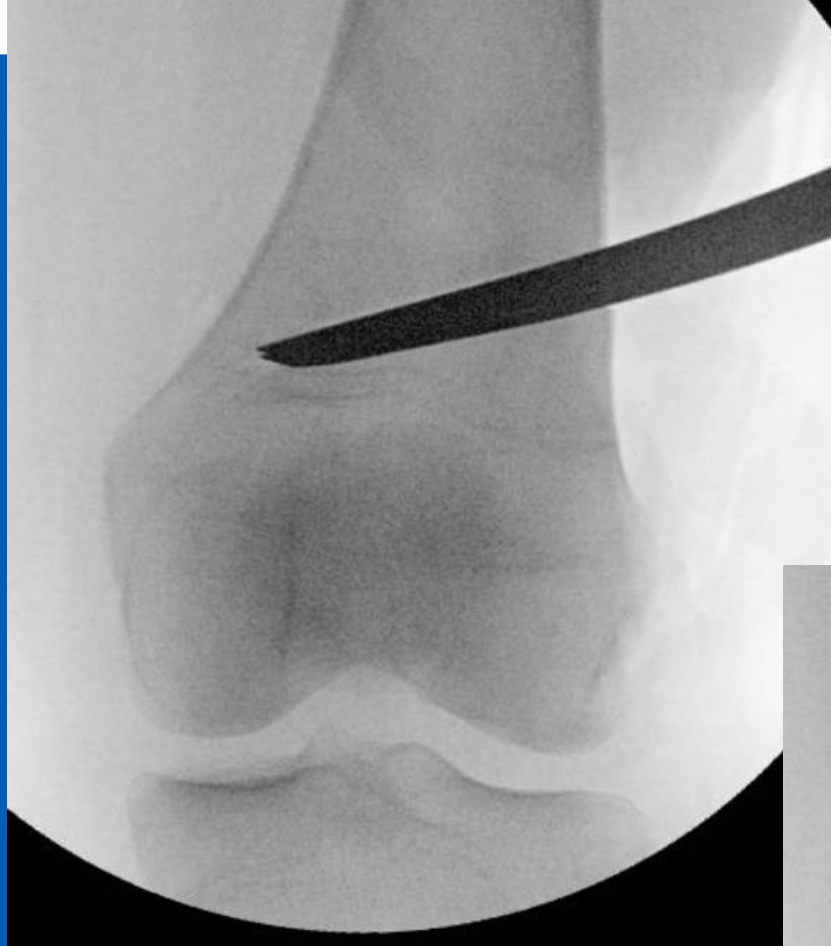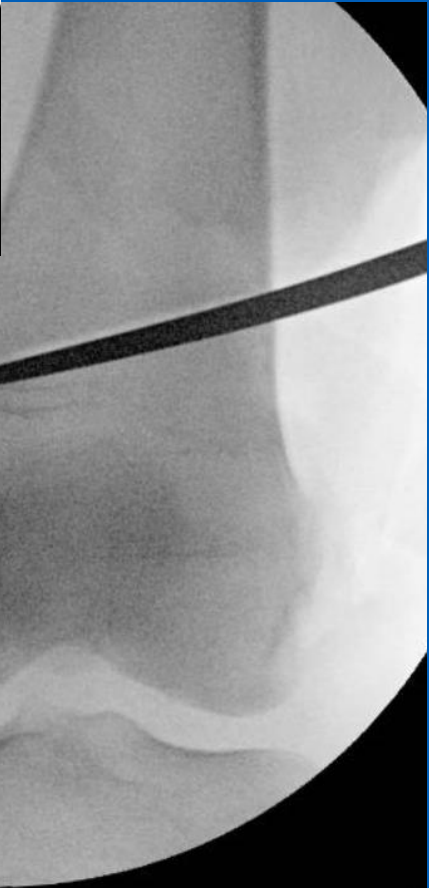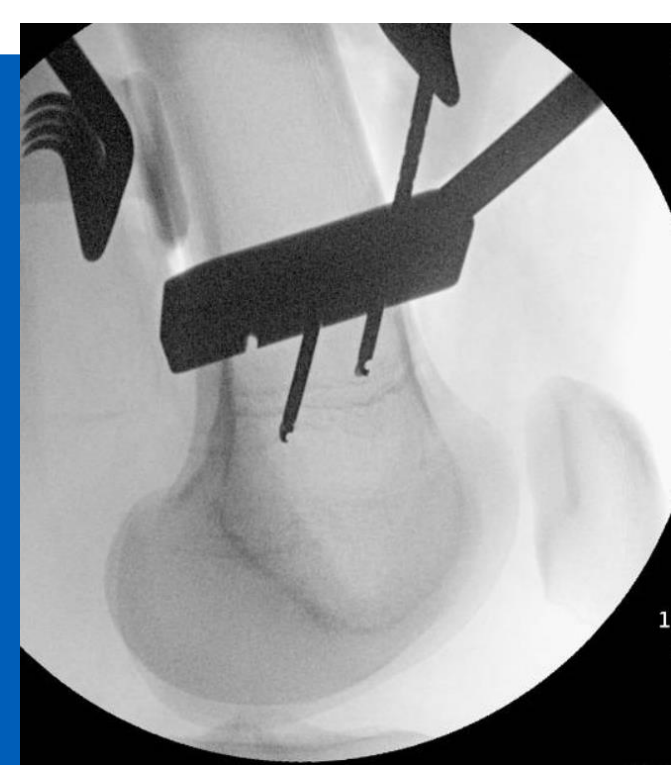- Hemiepiphysiodesis
 - Screw or plate technique
- Distal femoral osteotomy
 - Opening lateral or closing medial techniques
- Femoral anteversion and tibial torsion derotation

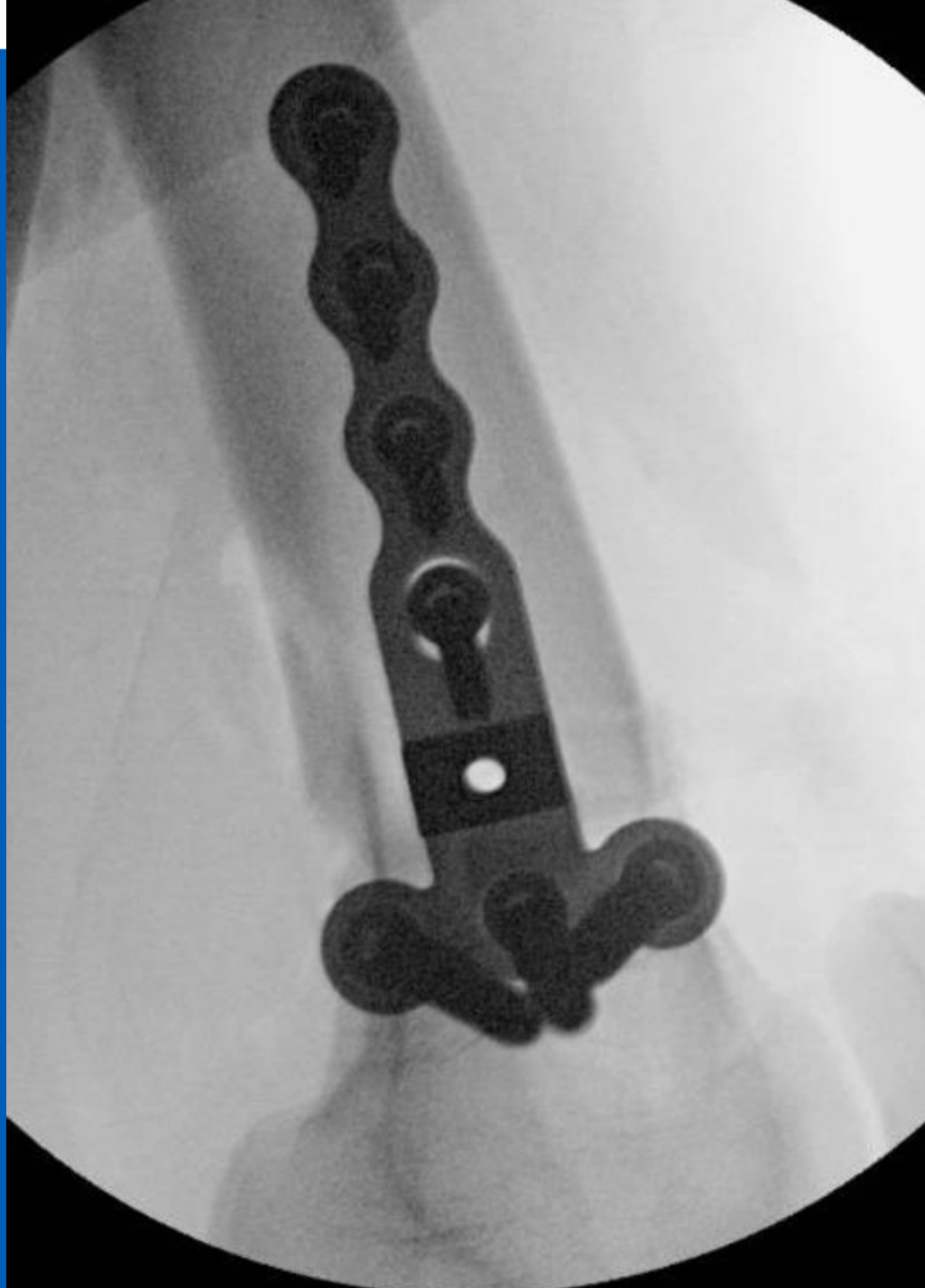
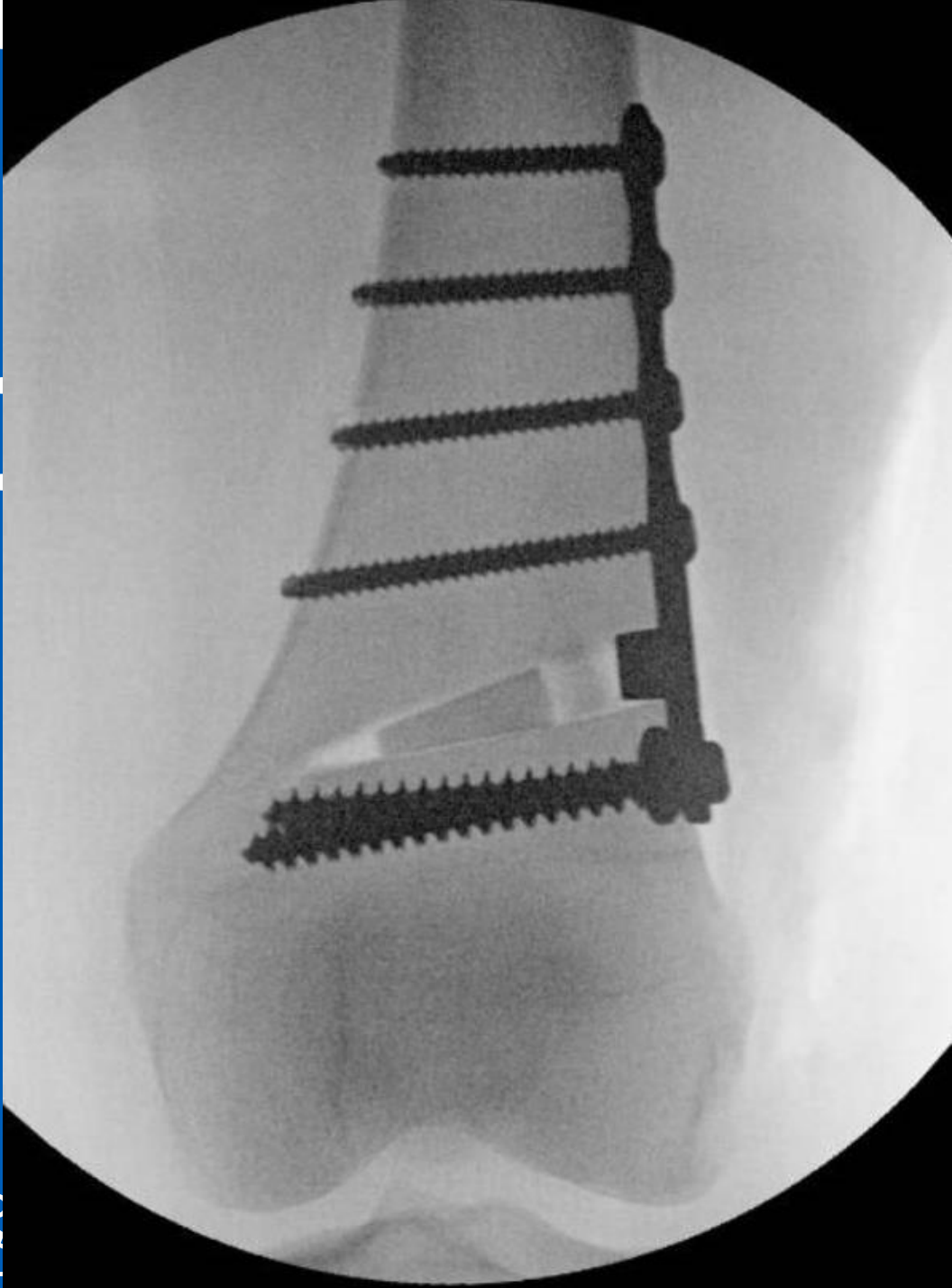
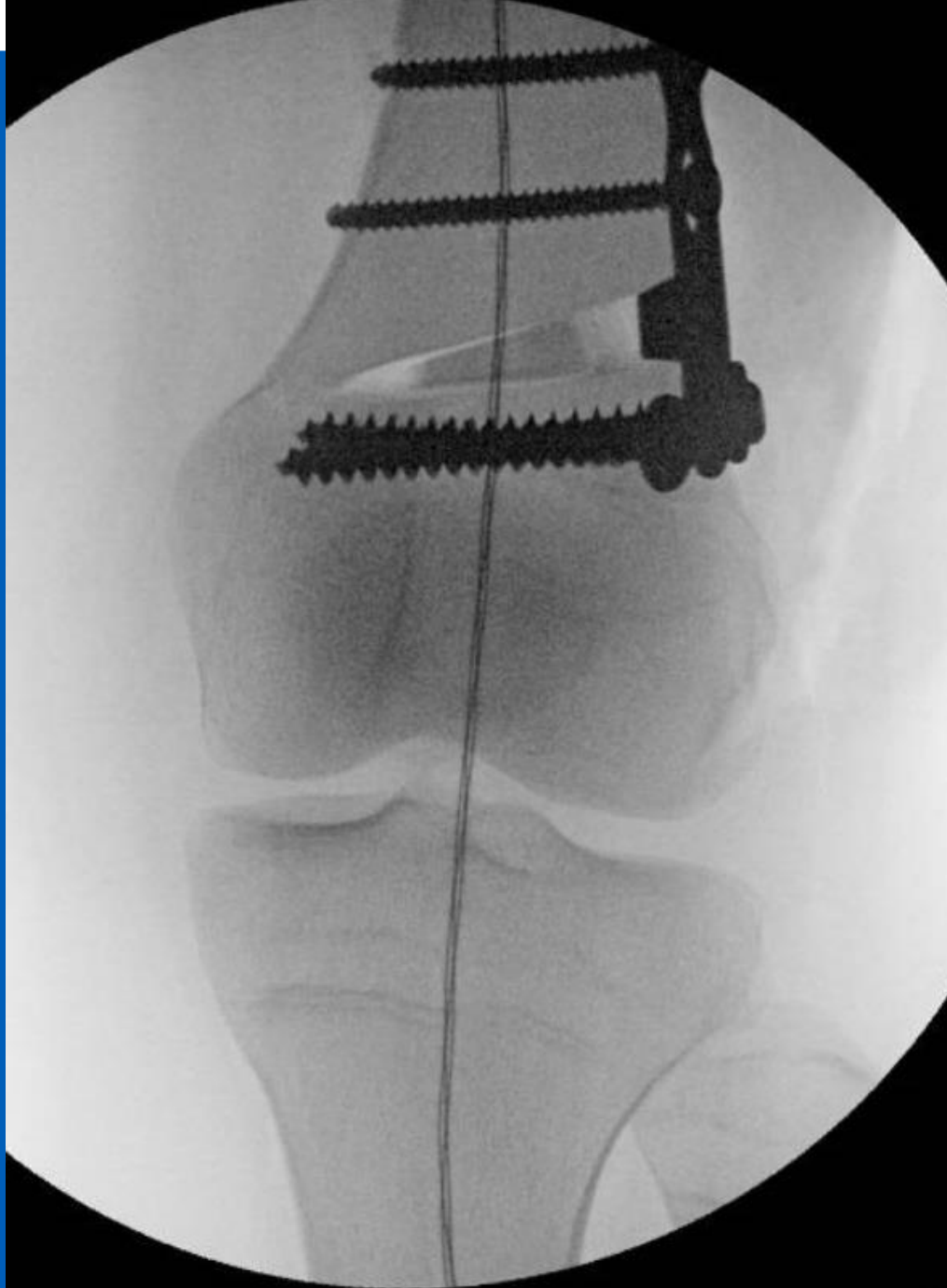Distal Femoral Osteotomy

- Genu valgum correction for skeletally mature patients
- Several papers have shown doing this alone can resolve patellar instability if this is considered the major factor

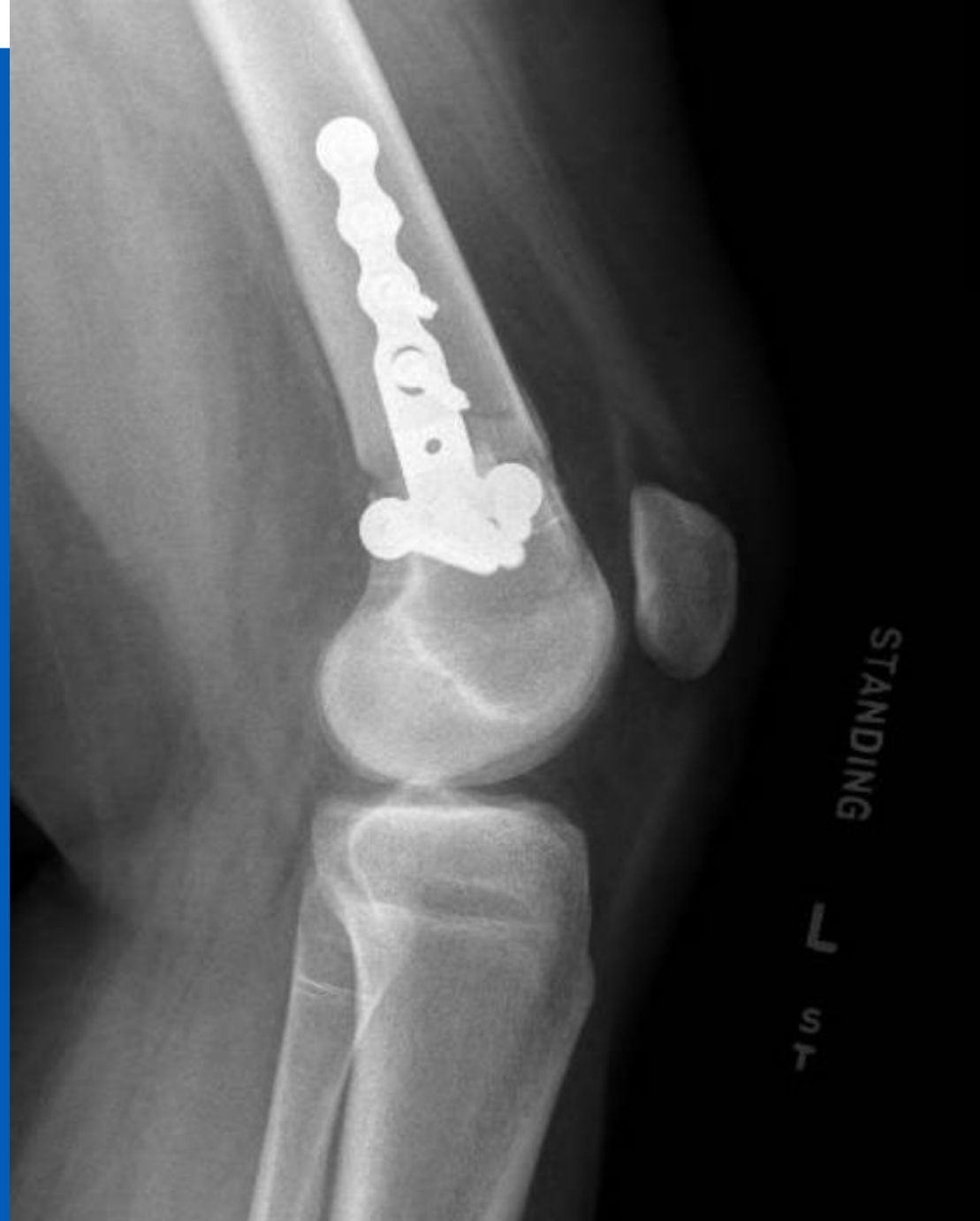
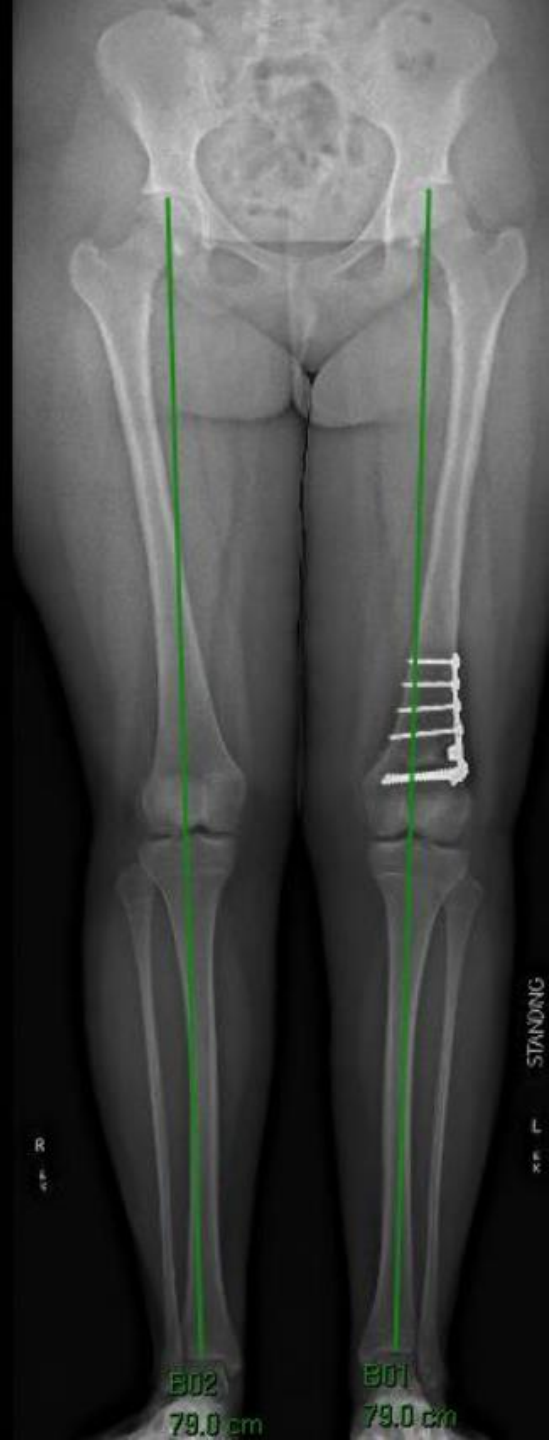






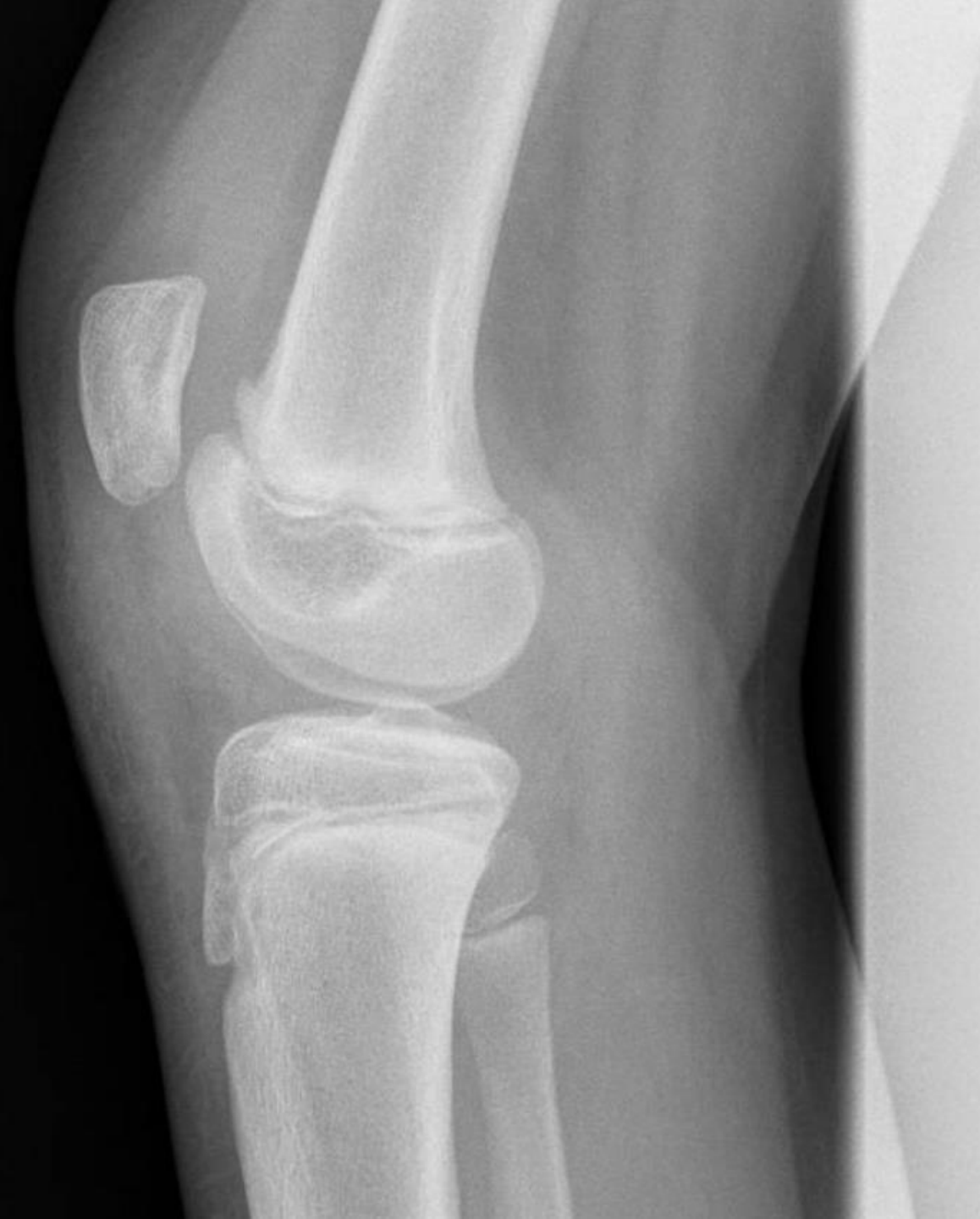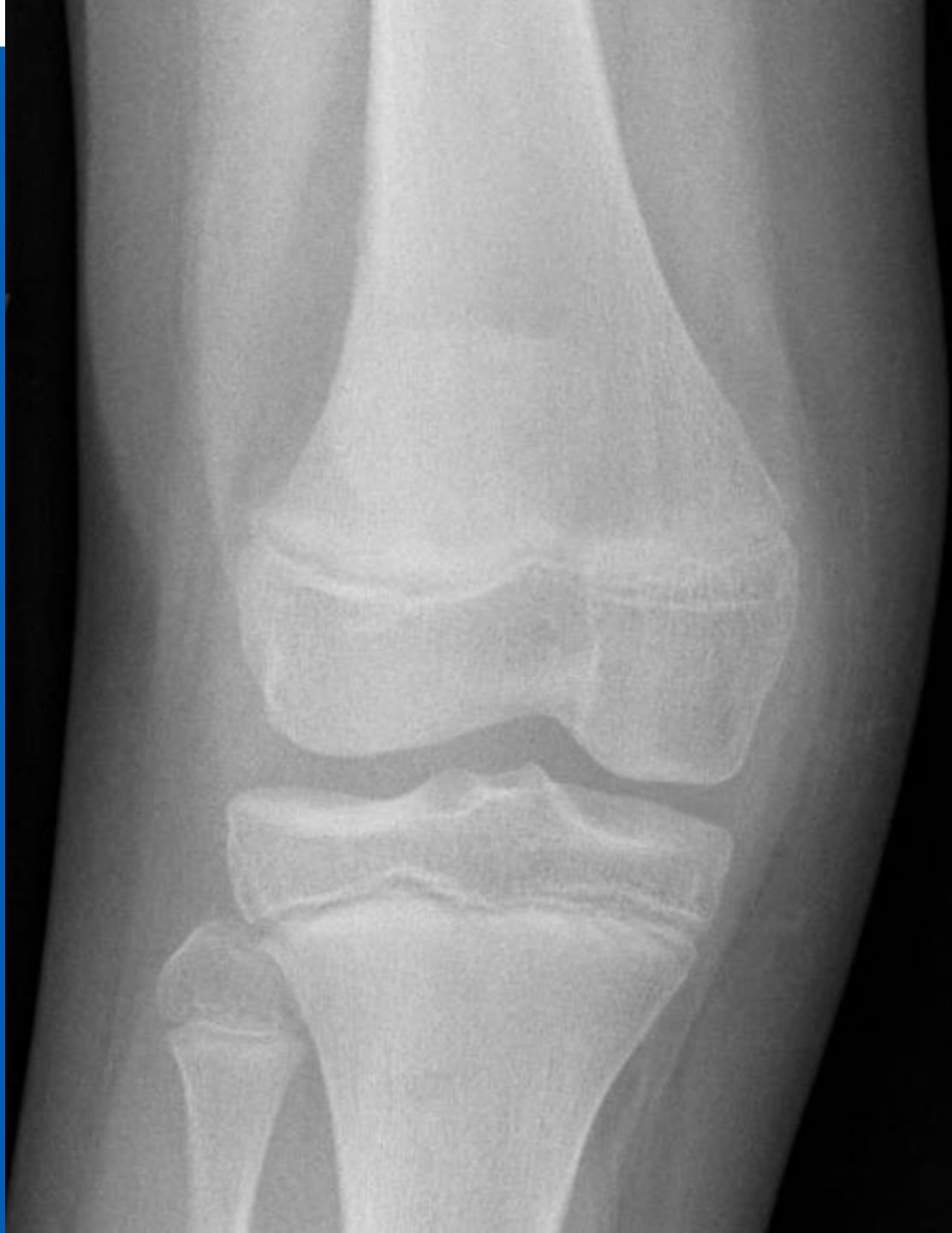Post Op



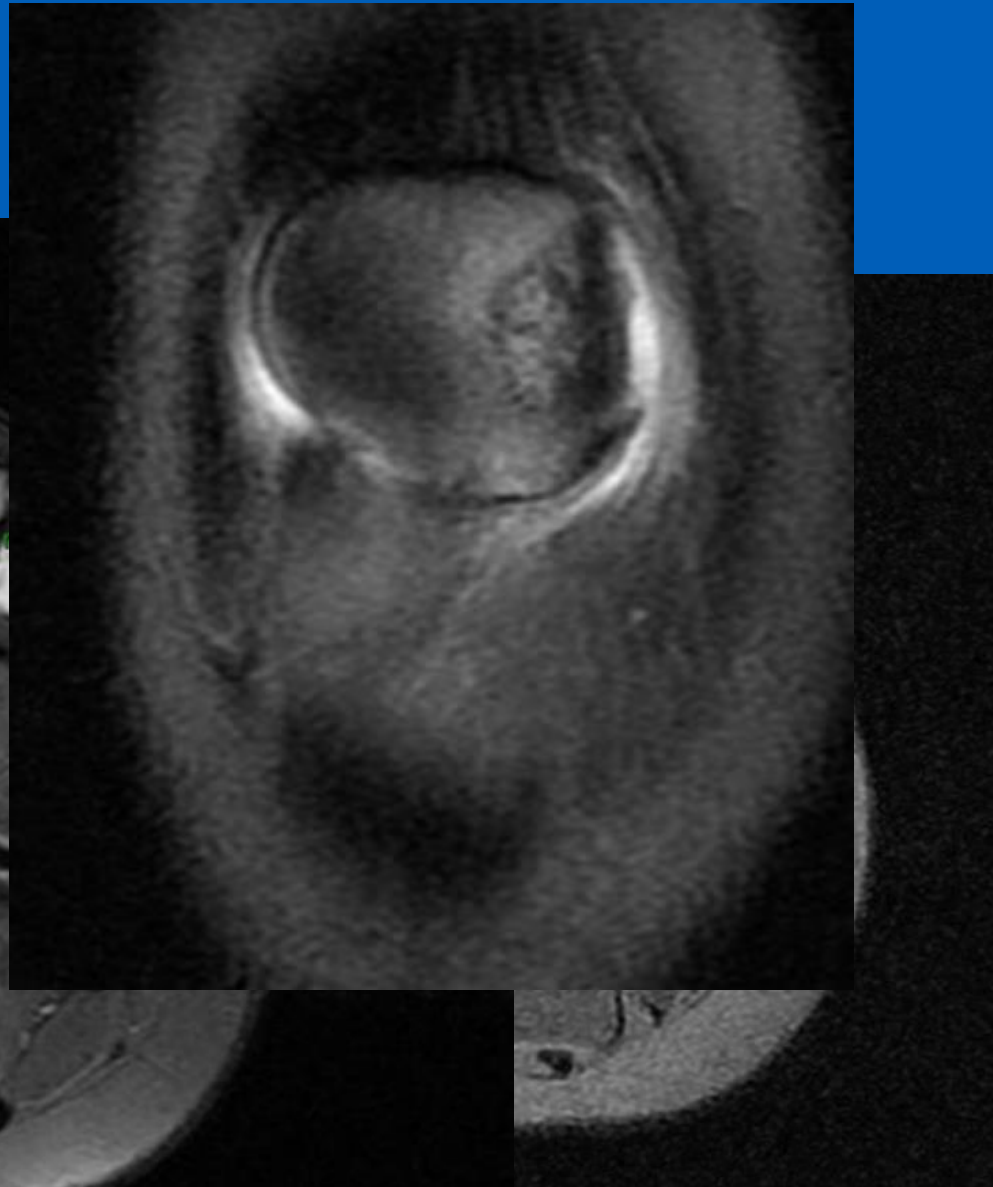
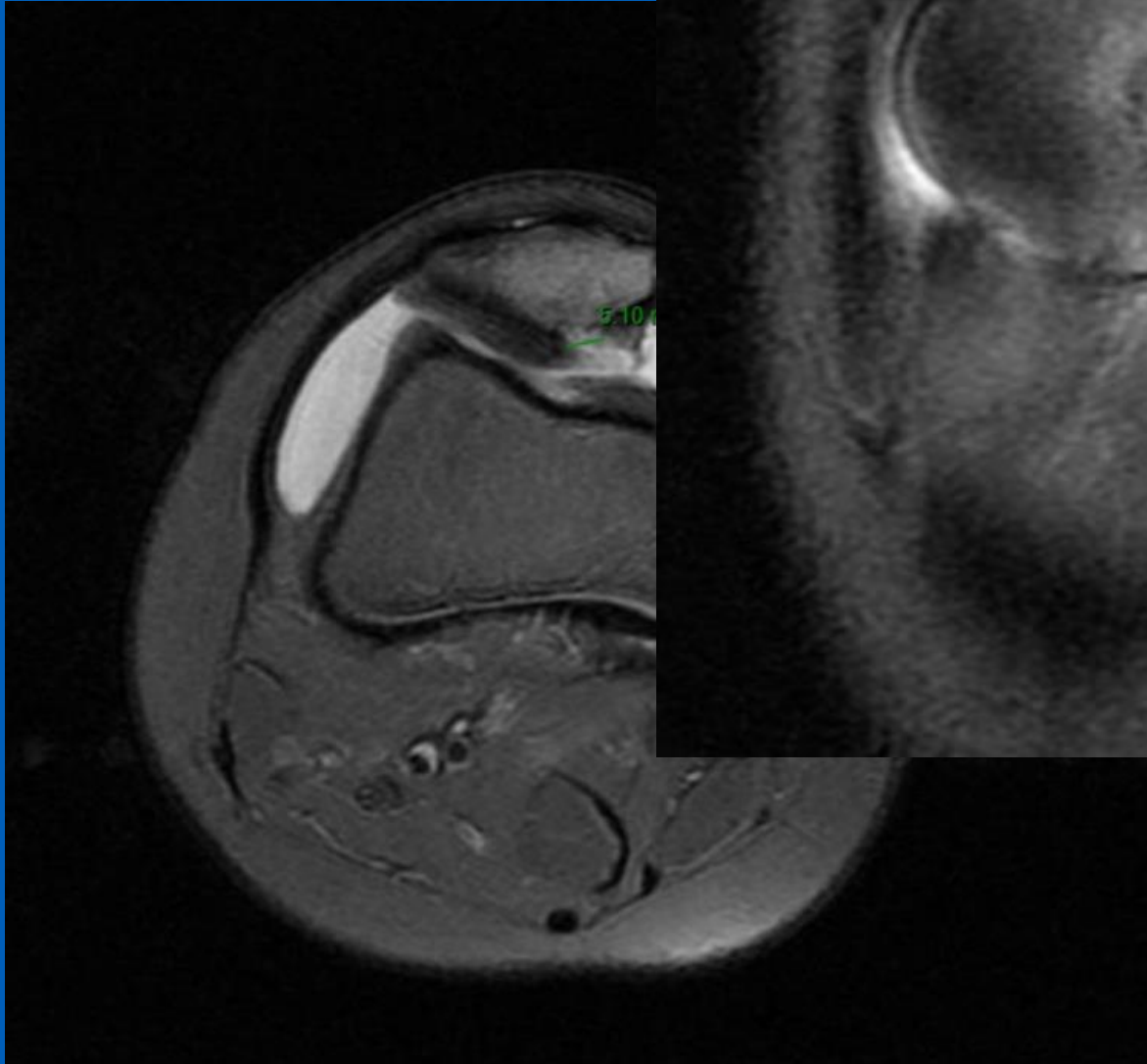
Case 1 (9yo F)

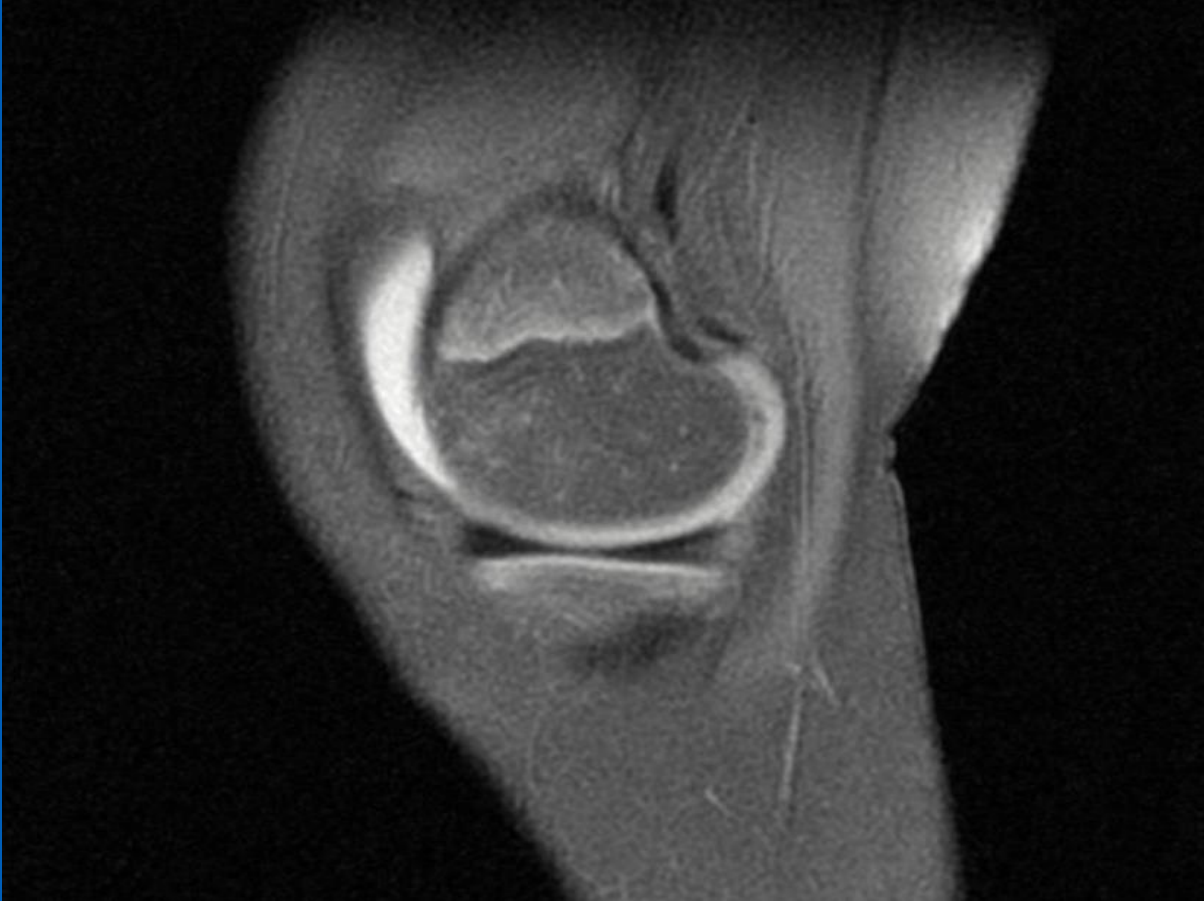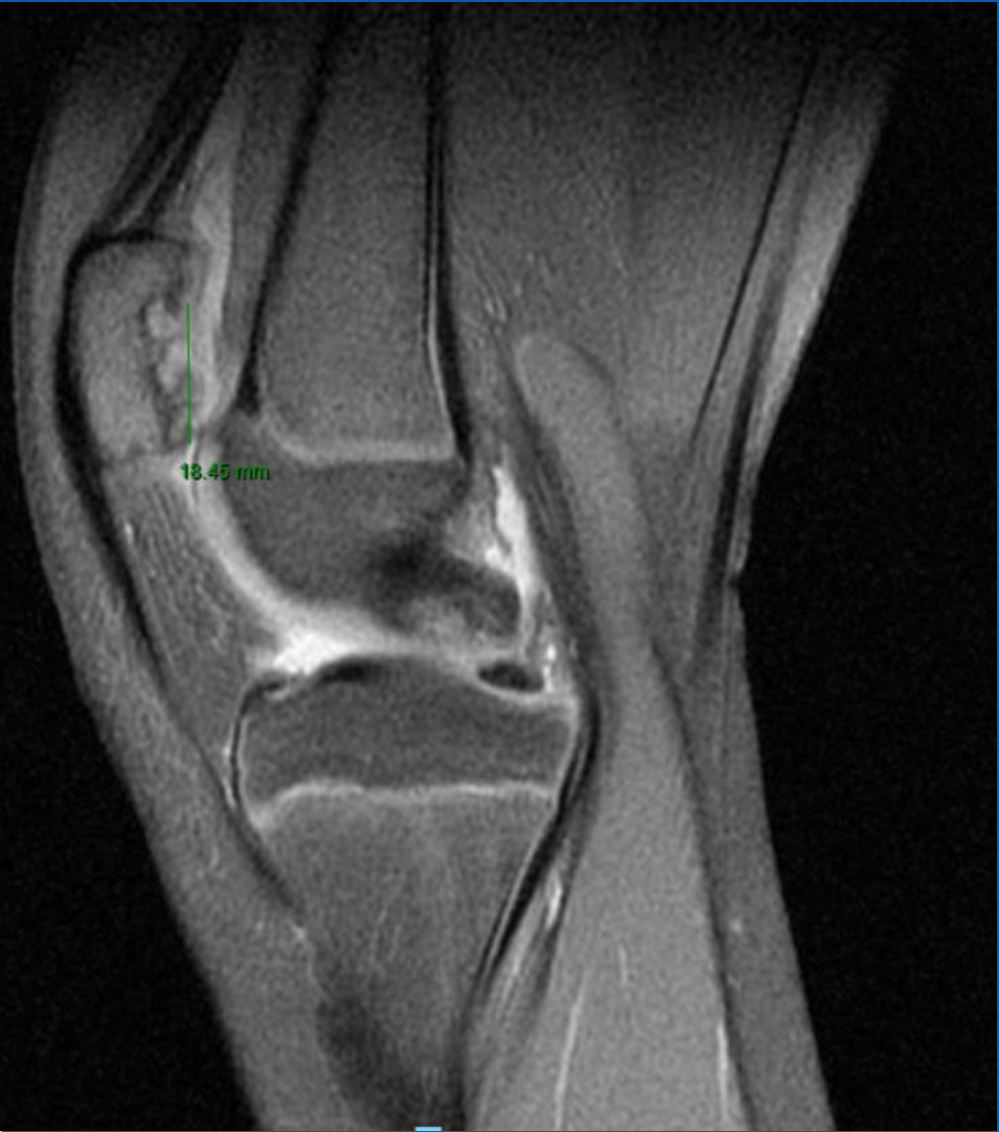- HPI: Initially injured knee in November 2020 when she had a scooter accident at school. Had possible instability event at that time and 2 more subsequent events with spontaneous reductions.
- Exam: 3 quadrant lateral glide prior to guarding. Positive apprehension sign. Genu valgum alignment. Mildly positive J-sign in full extension

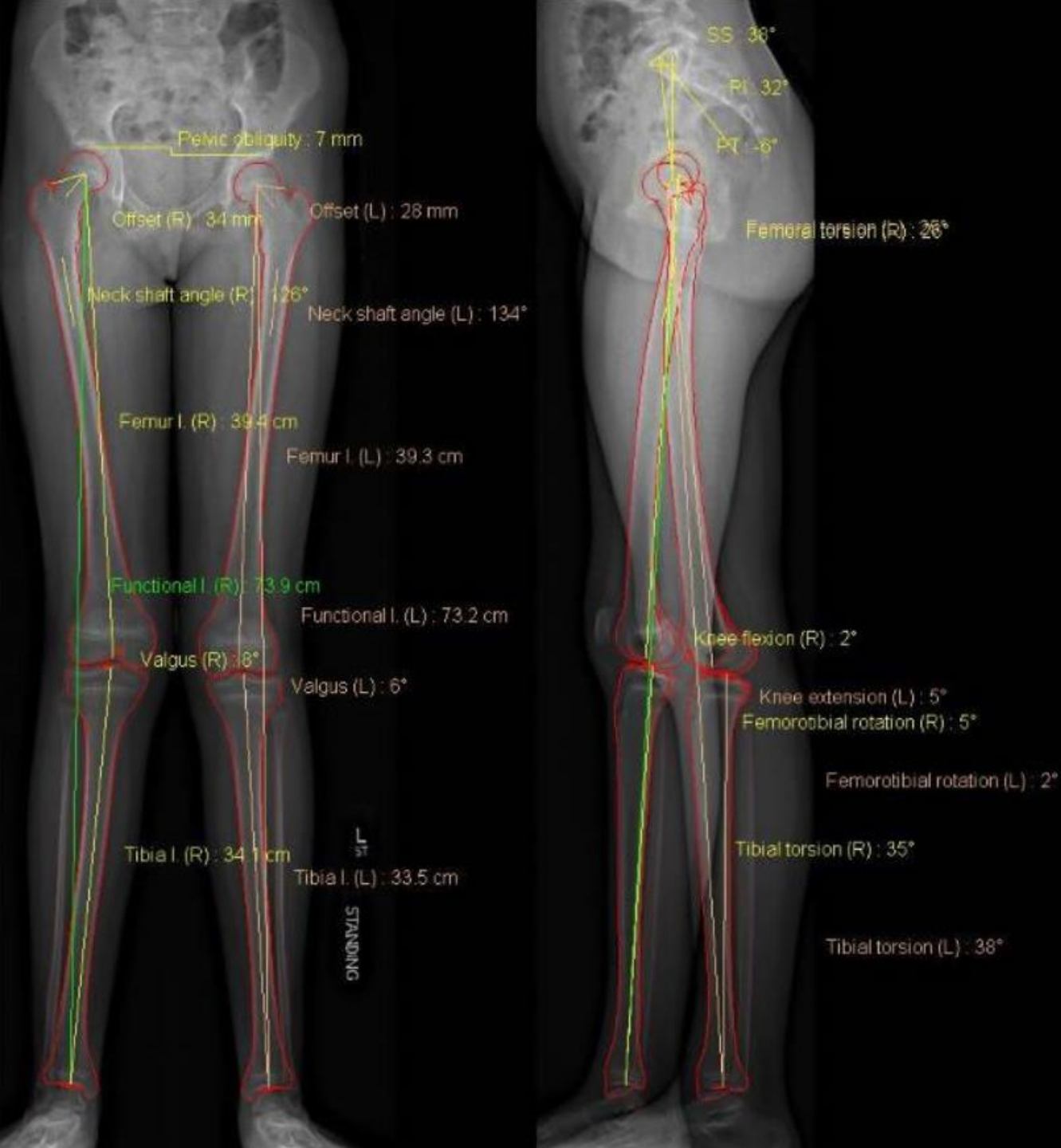




MRI







Lengths (3)	Right	Left	
Femur length	39.4 cm	39.3 cm	
Tibia length	34.1 cm	33.5 cm	
Functional length	73.9 cm	73.2 cm	
Anatomical length	73.5 cm	72.8 cm	

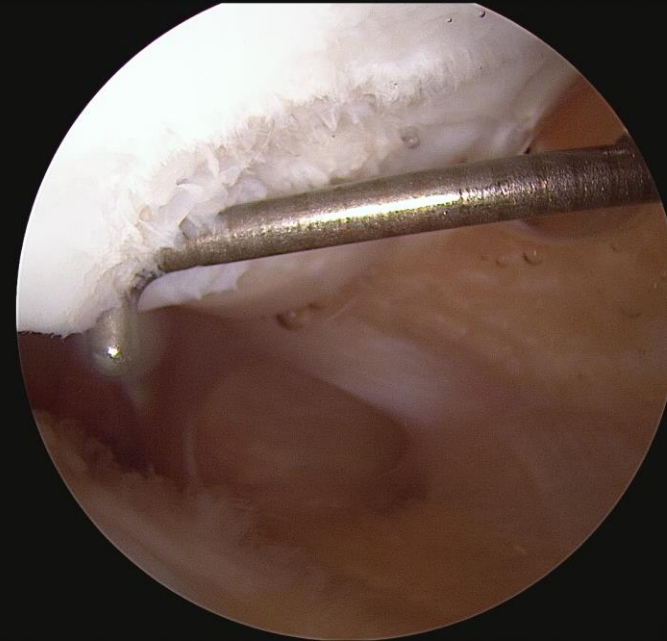
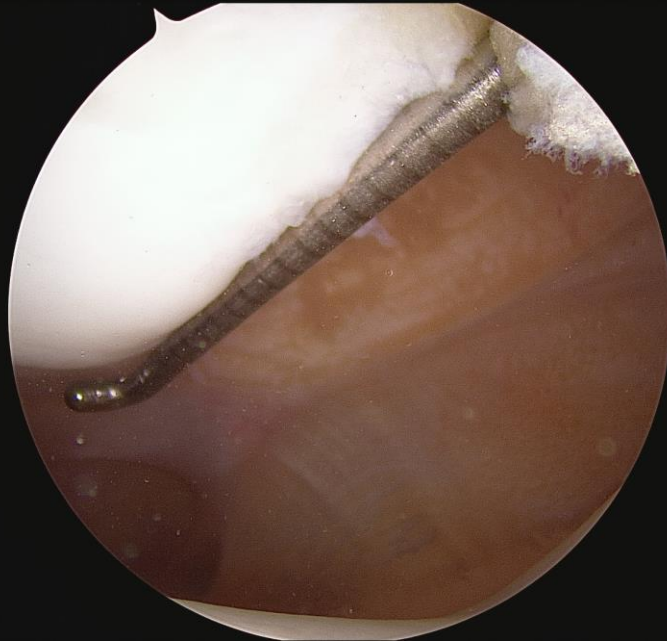
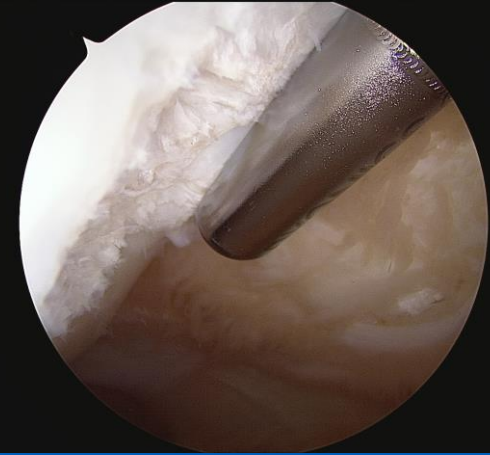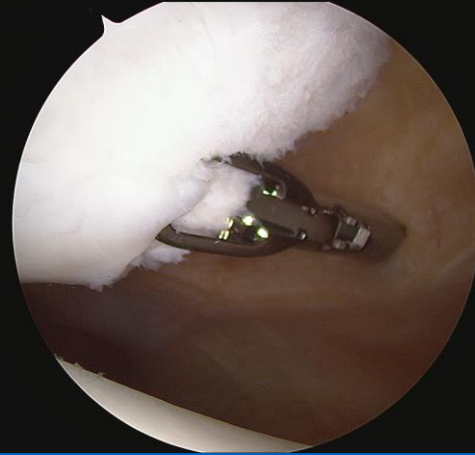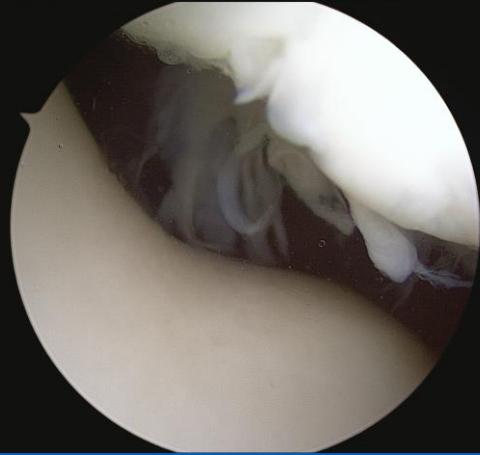
Femur (3)	Right	Left	
Femoral head diameter	35 mm	37 mm	
Neck length	41 mm	38 mm	
Neck shaft angle	126°	134°	
Femorol offset	34 mm	28 mm	

Knee (4)	Right	Left	
Valgus/Varus	Valgus 8°	Valgus 6°	
Knee flexion/Knee extension	Flexion 2°	Extens. 5°	
HKS	3°	2°	
Femoral mechanical angle	97°	98°	
Tibial mechanical angle	93°	95°	

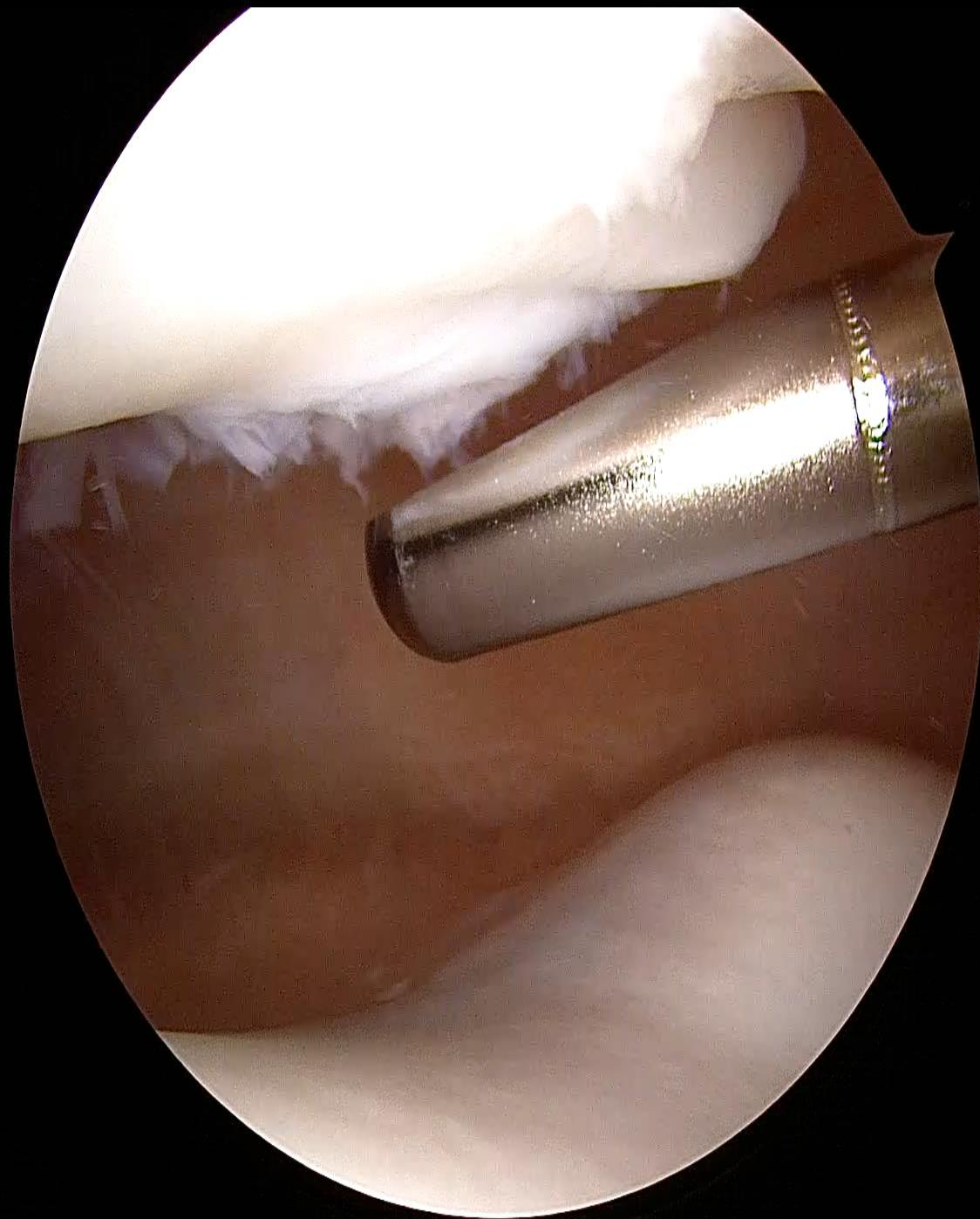
Torsions (4)	Right	Left	
Femoral torsion	26°	25°	
Tibial torsion	35°	38°	
Femorotibial rotation	5°	2°	

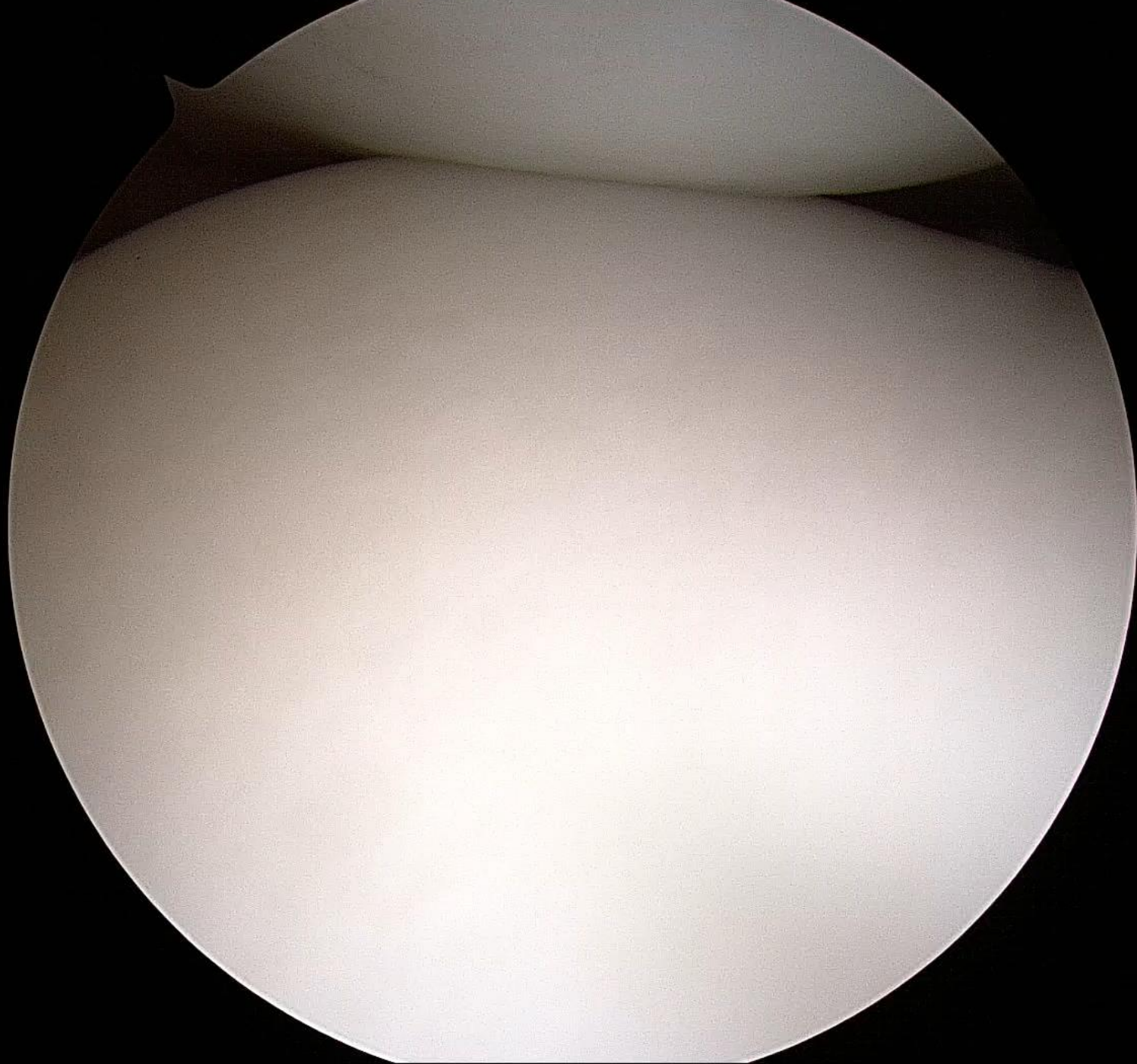

OR Arthroscopy

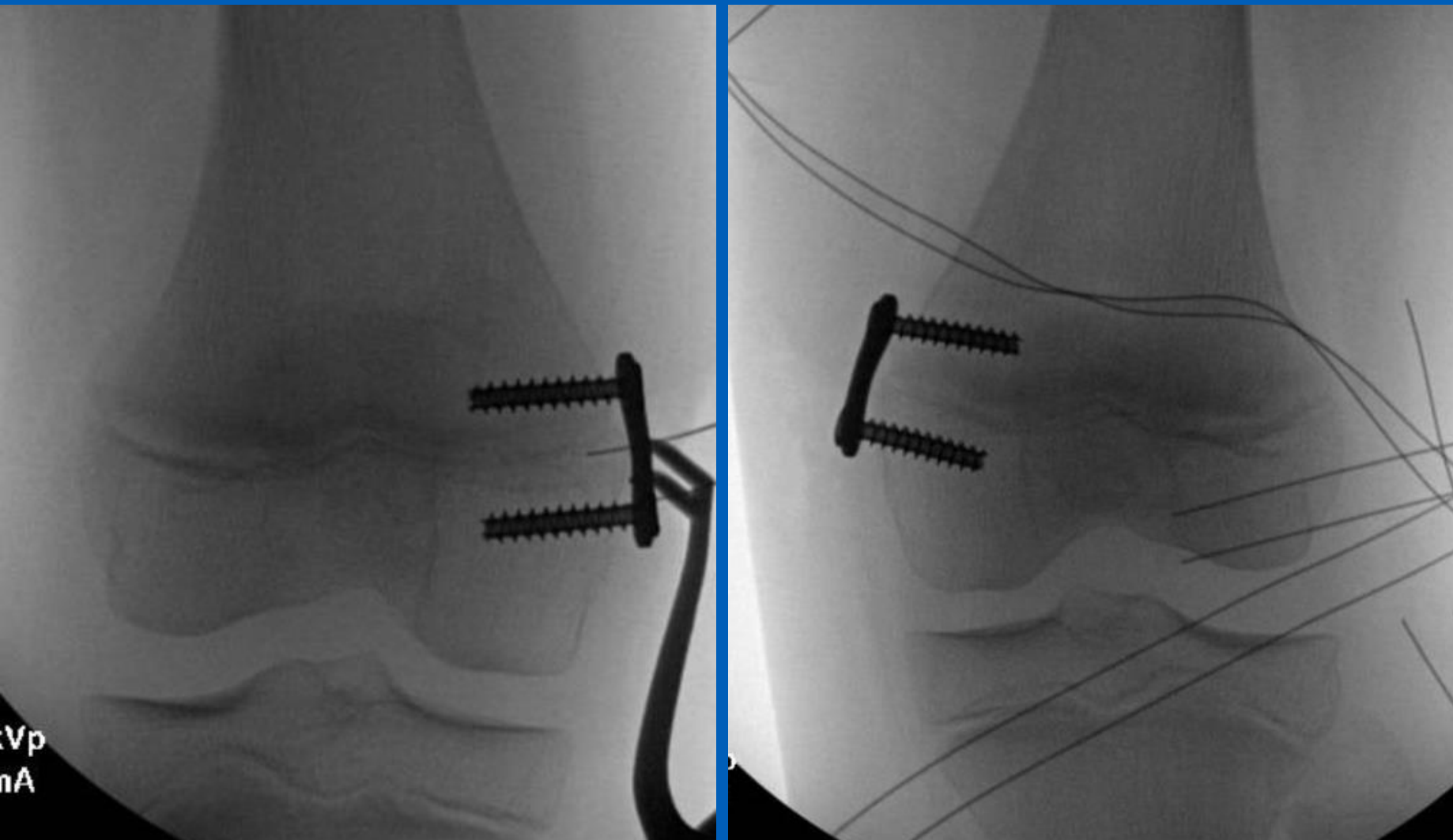


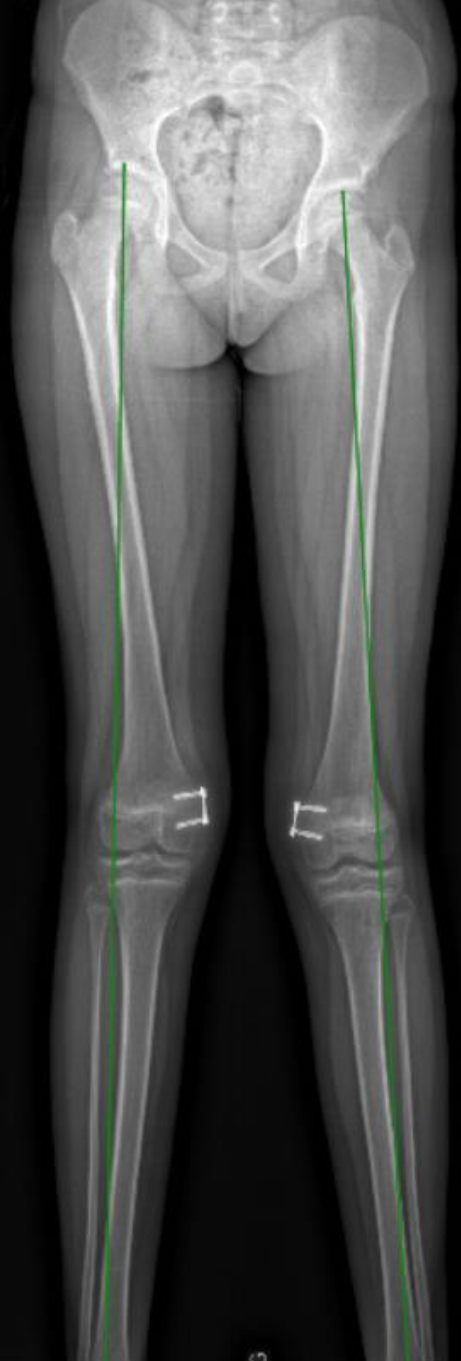Vid



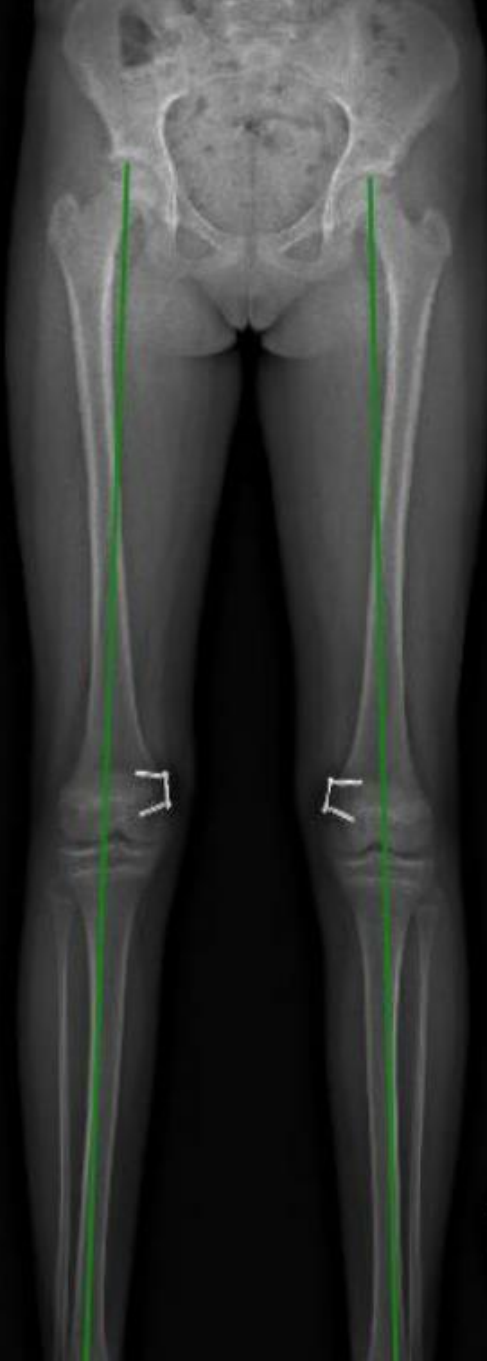

OR Guided Growth

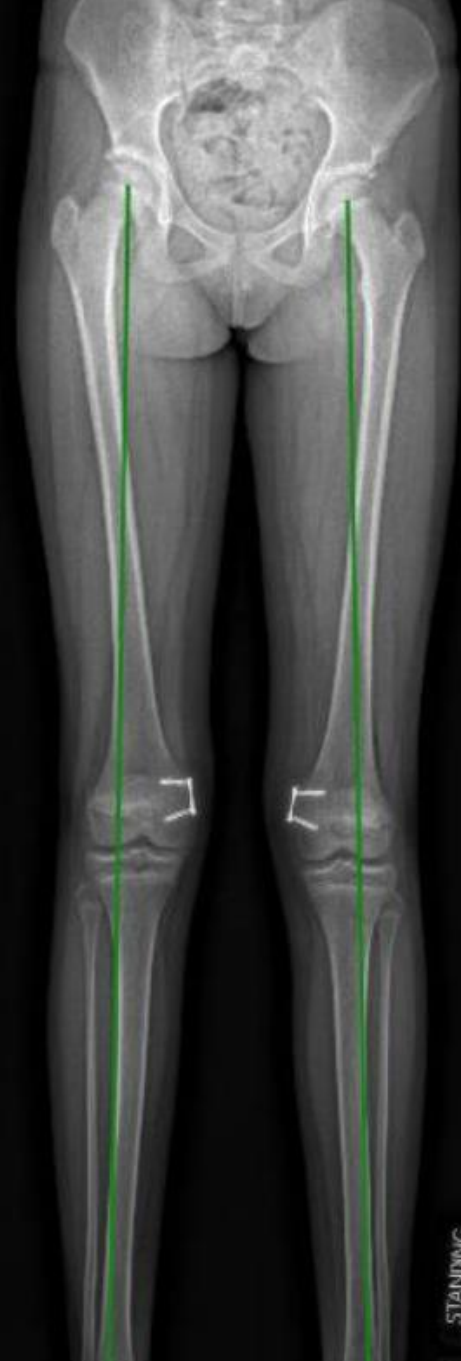



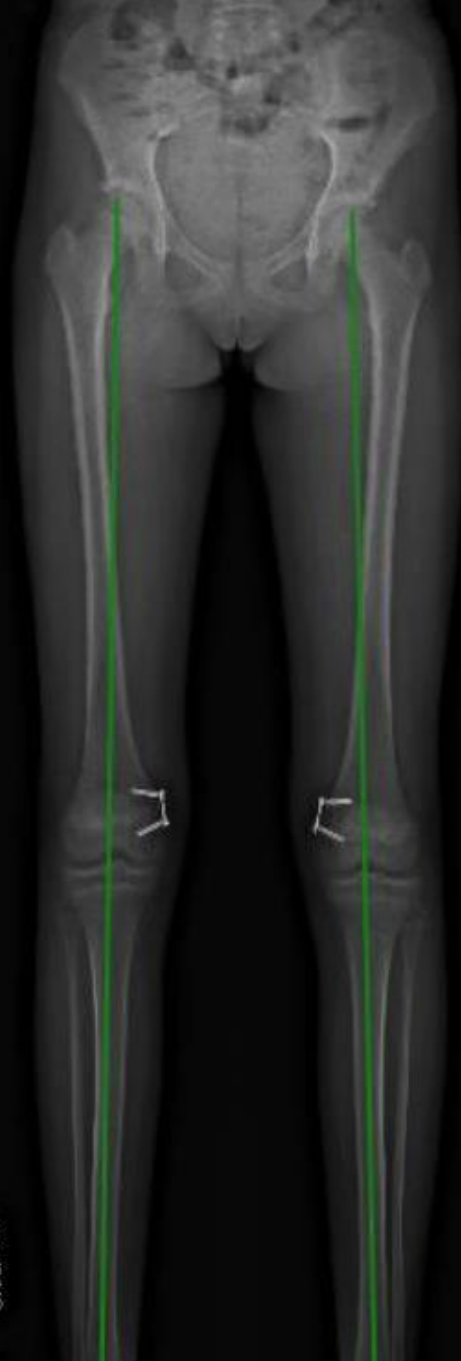2 months



6 months



9 months



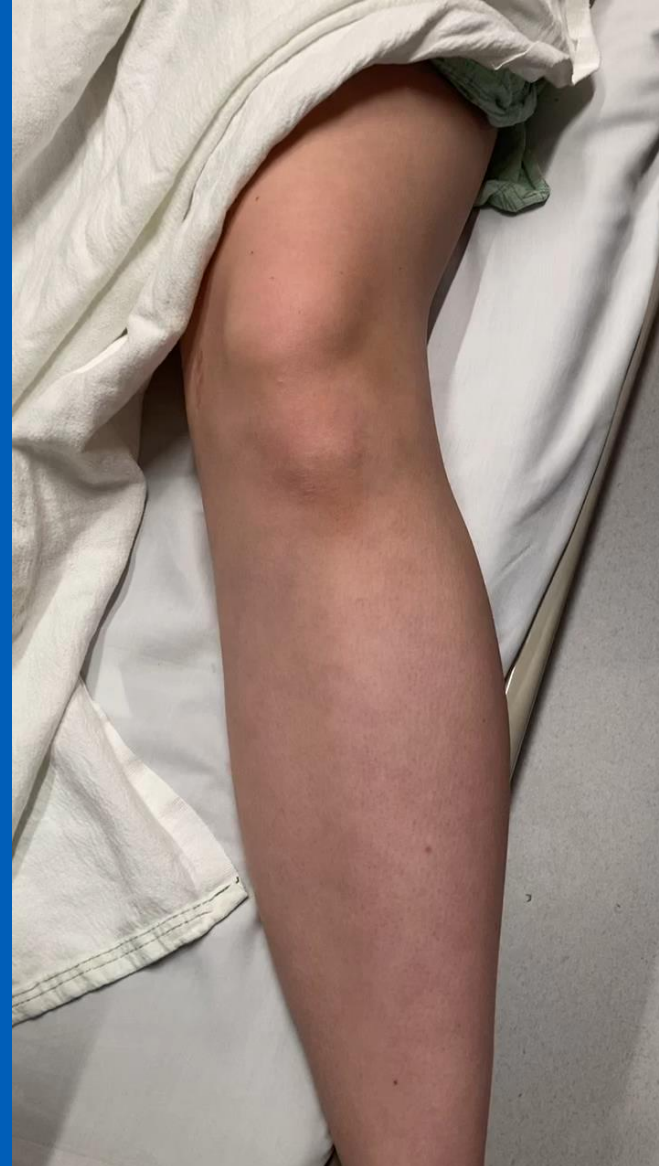12 months

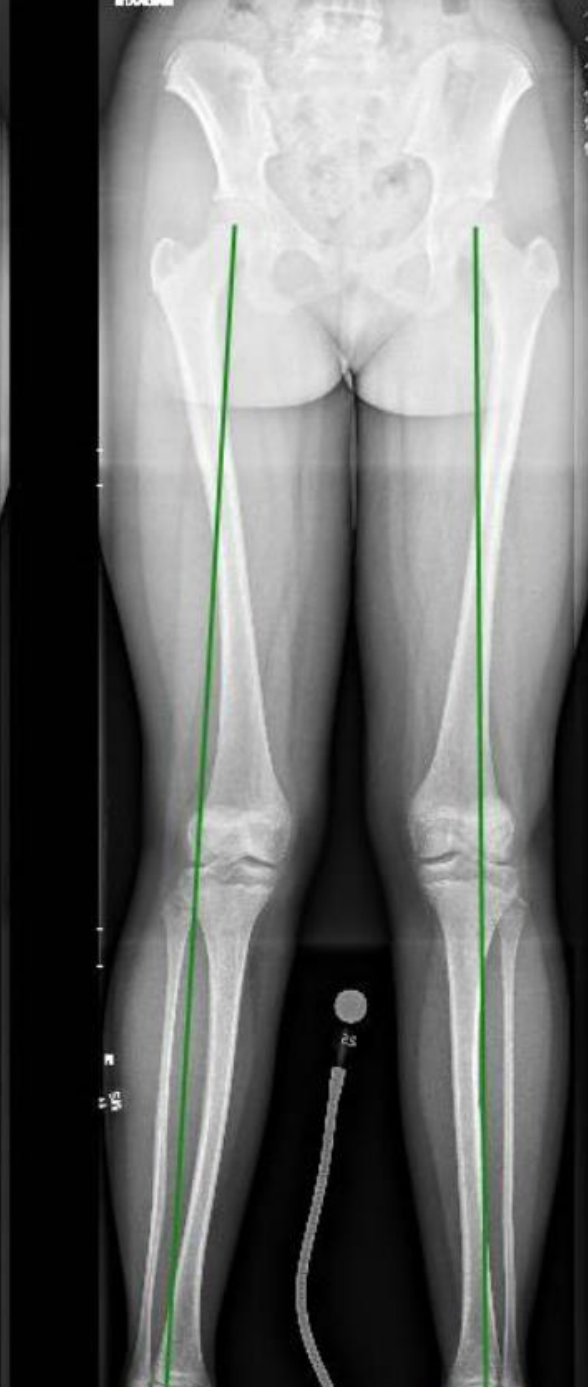
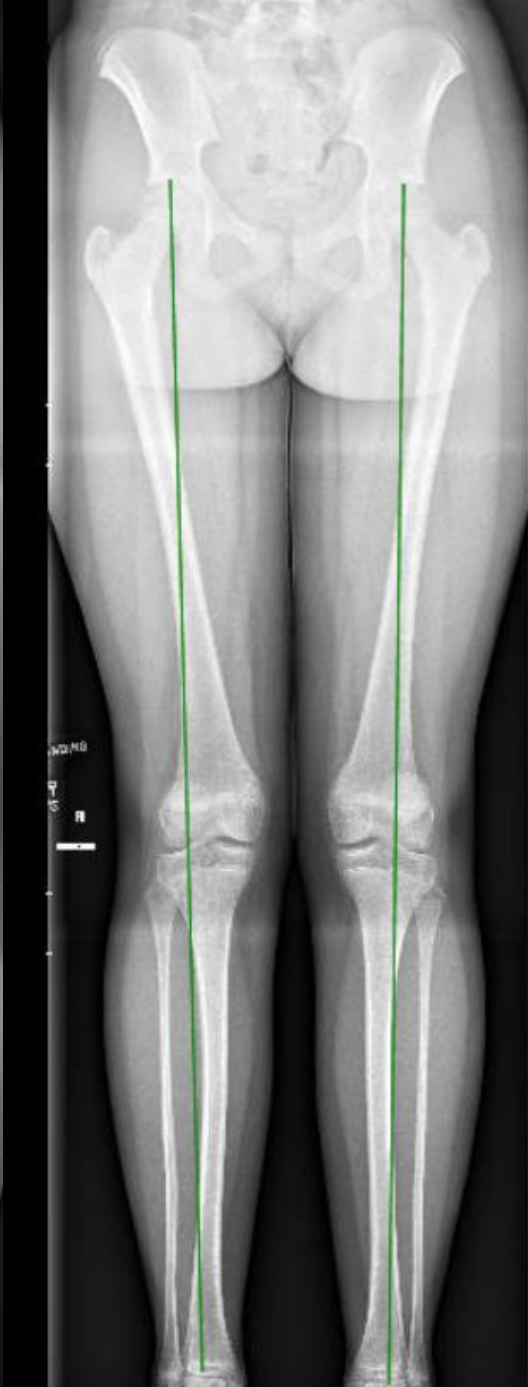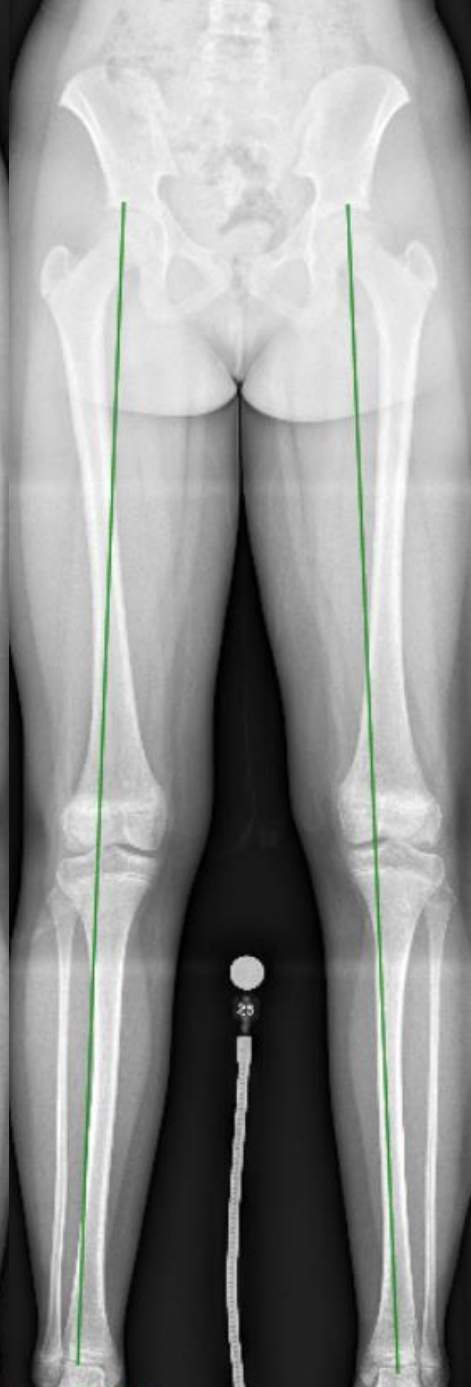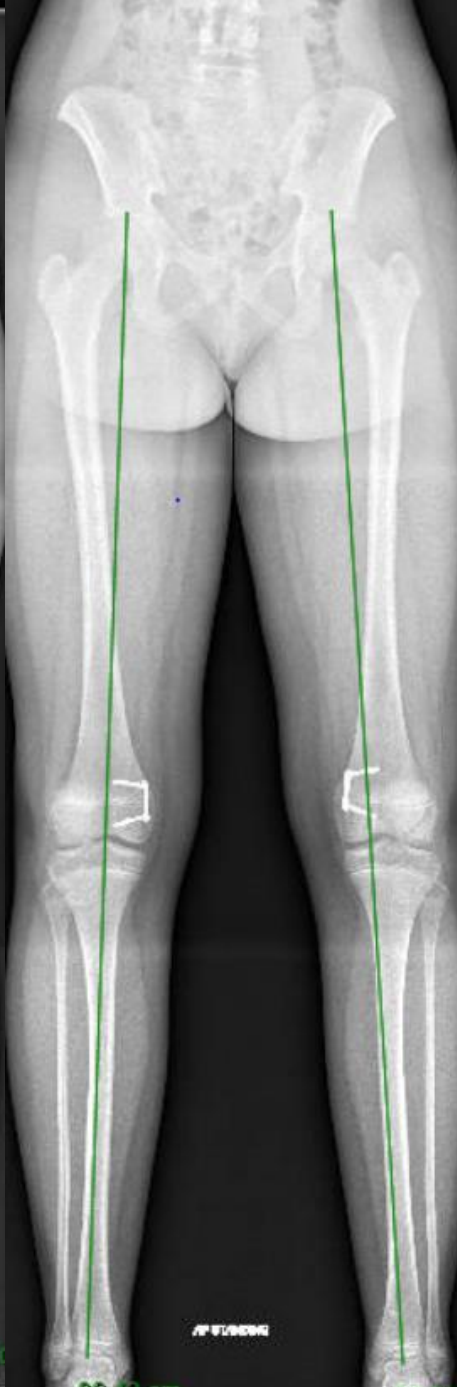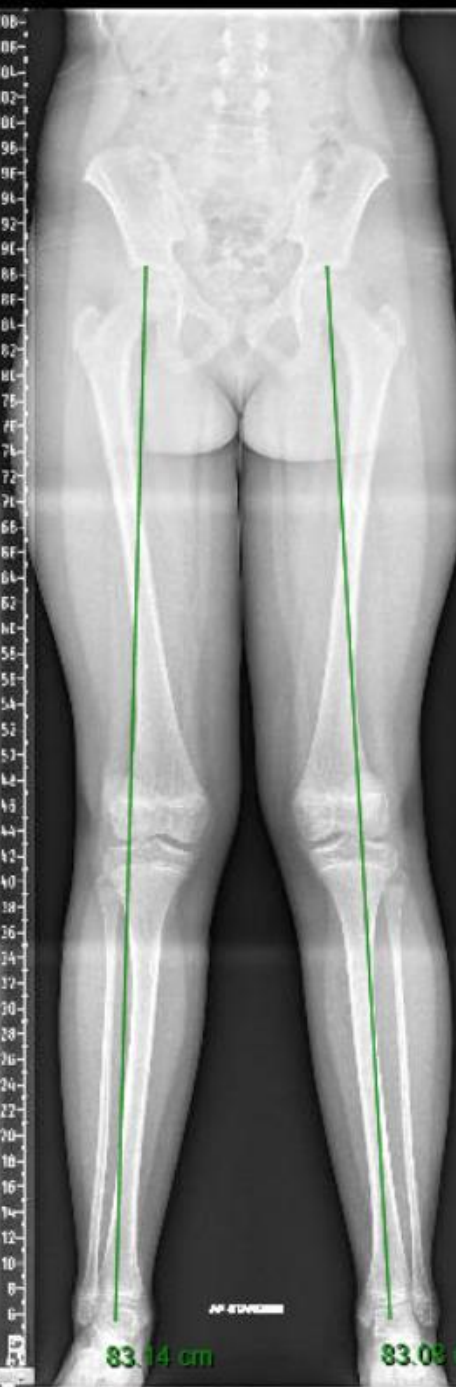Case 2 12yo F

- Daily patellar dislocations bilateral
- Previously underwent guided growth with recurrence
- Dislocating in brace with sports

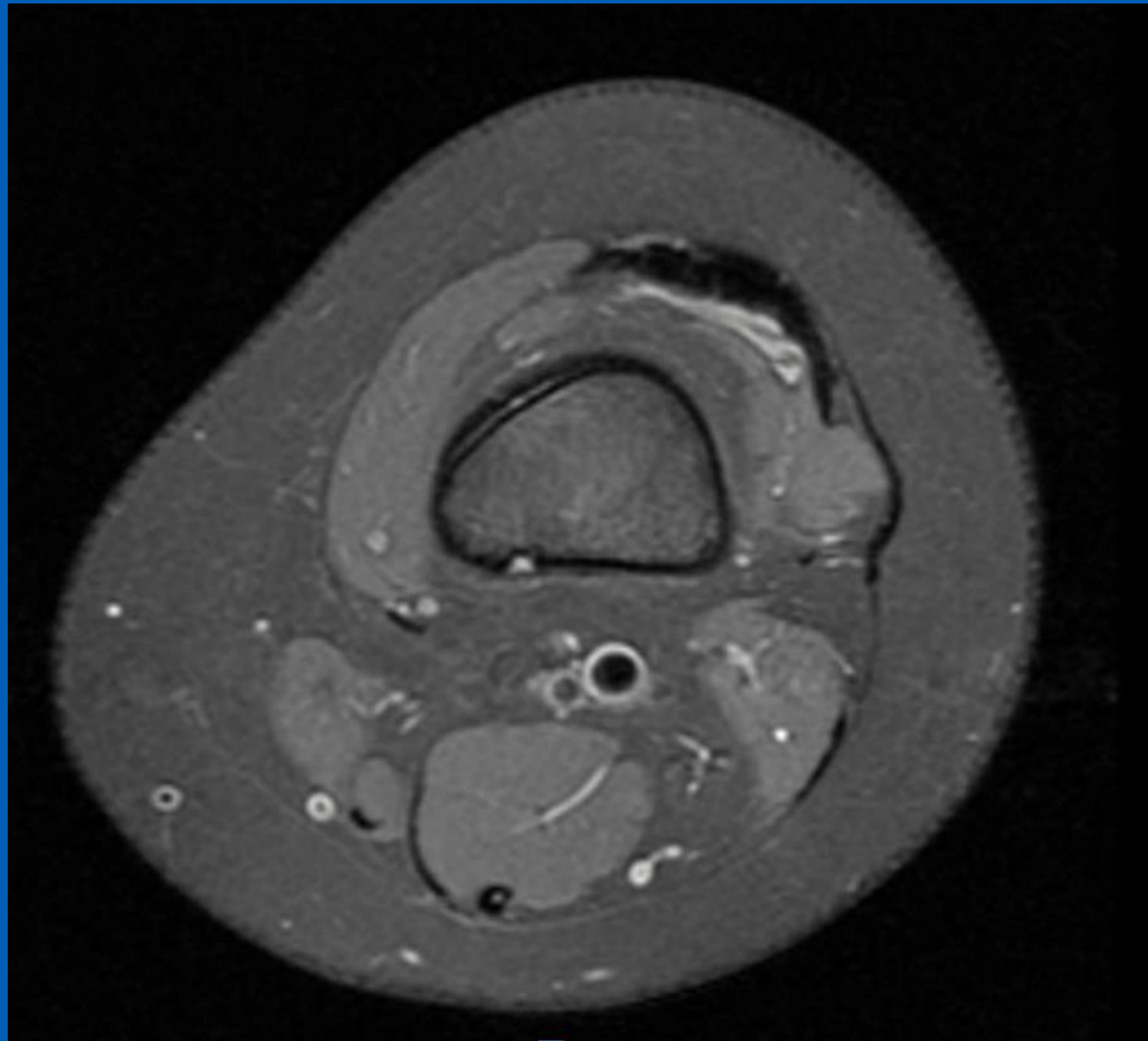


Exam

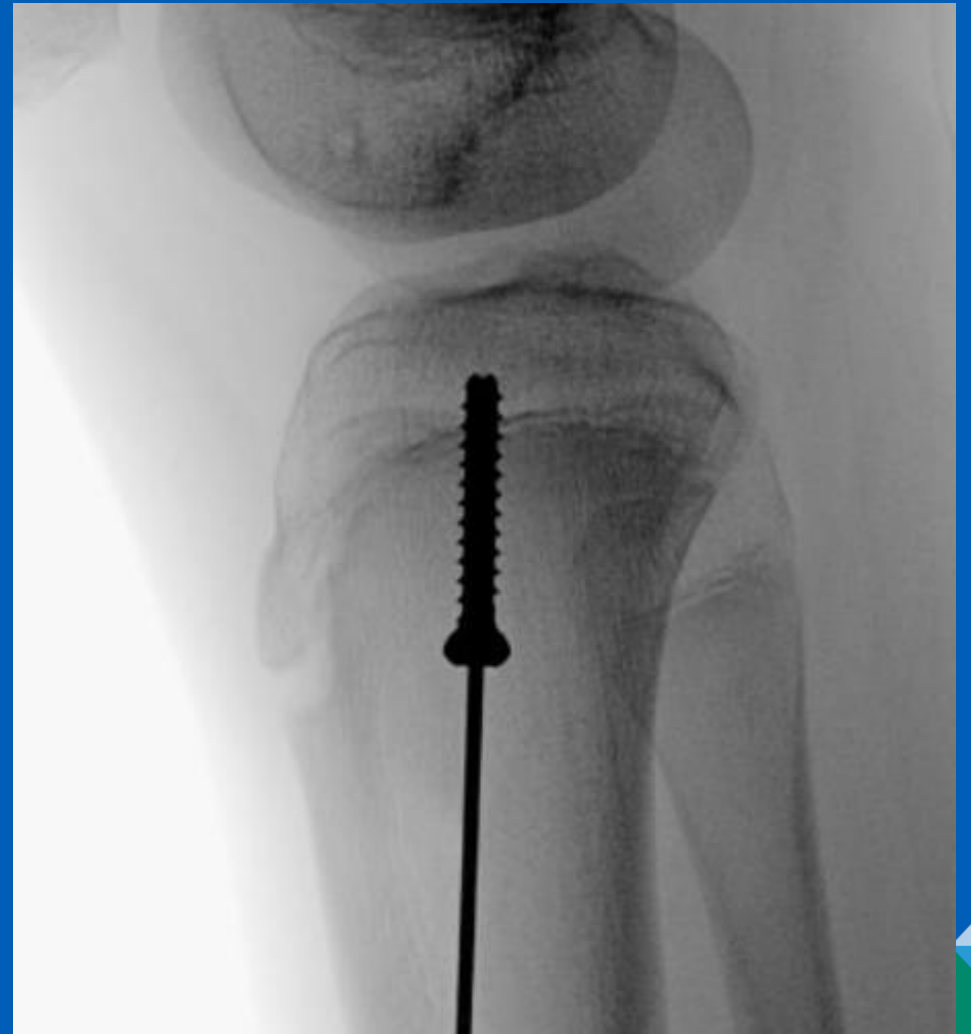
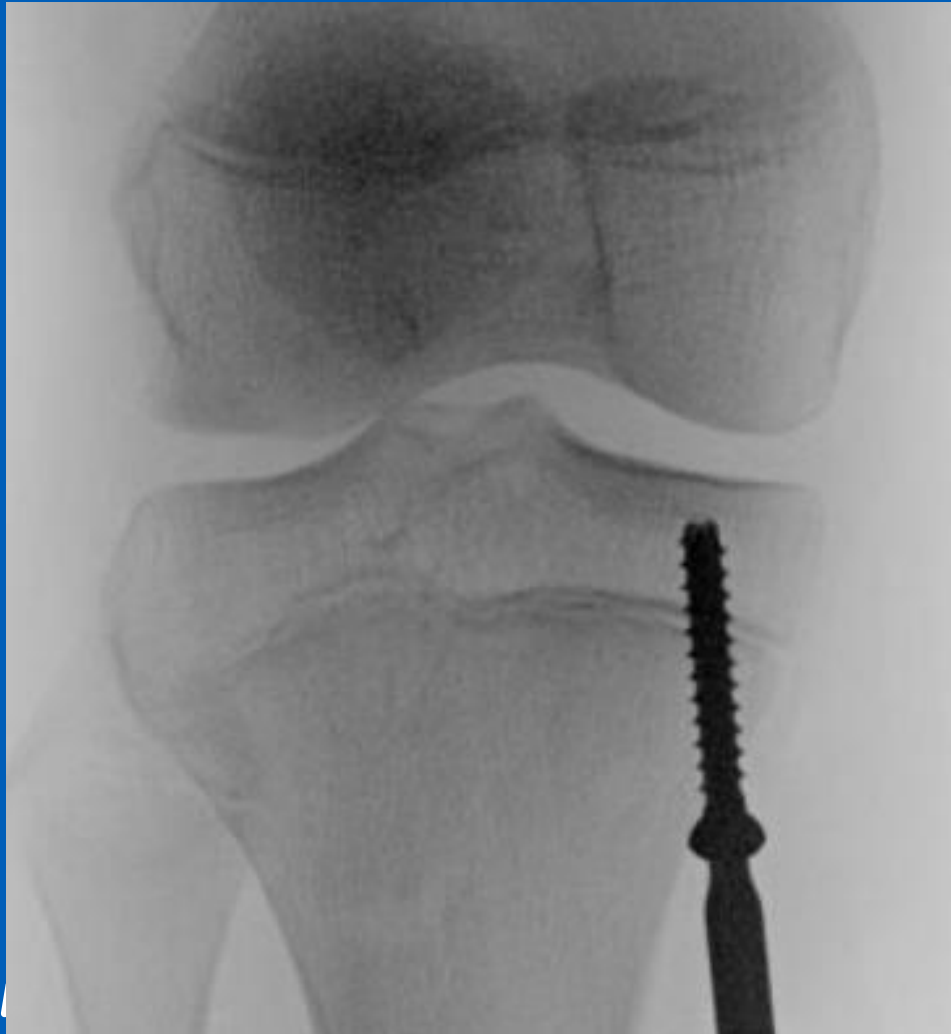



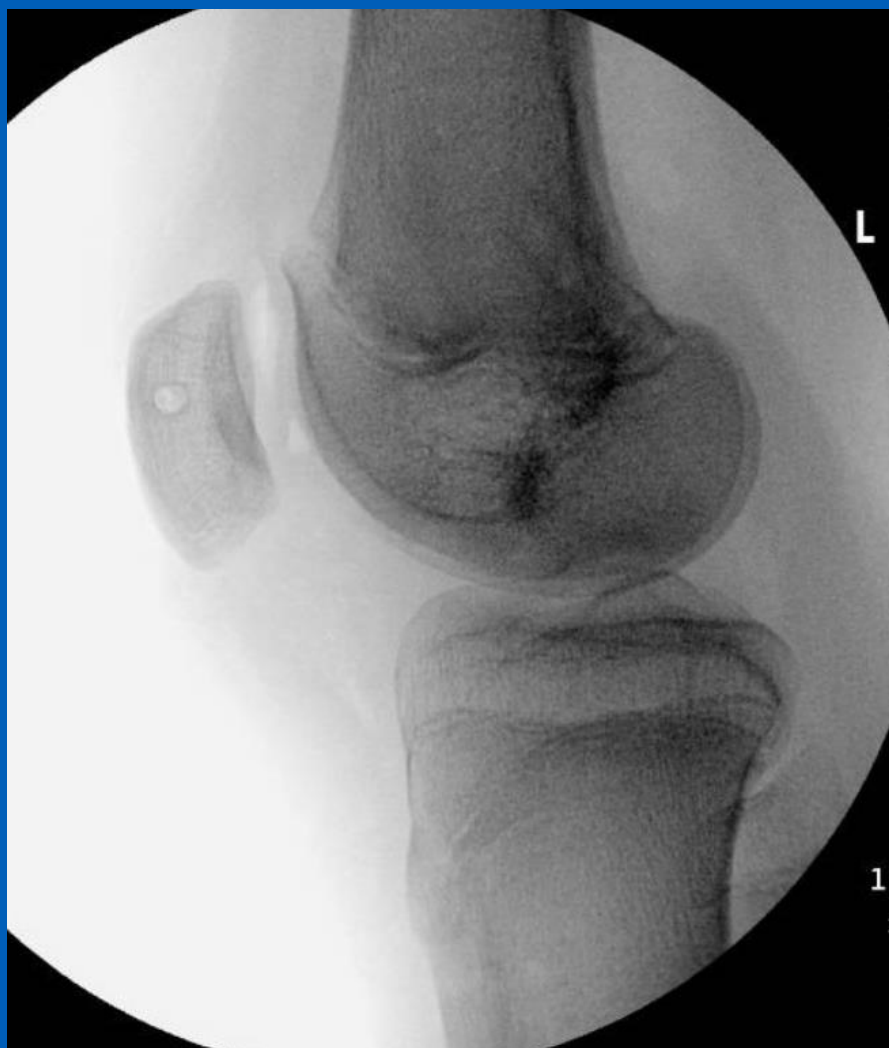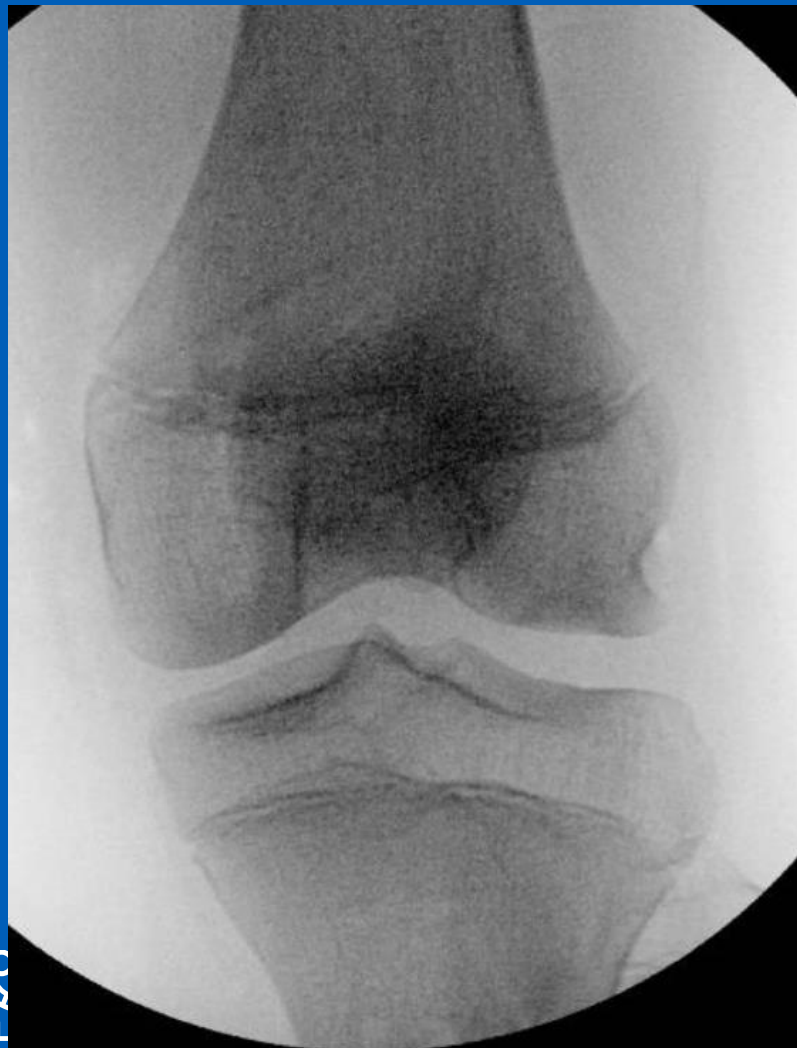MRI Left

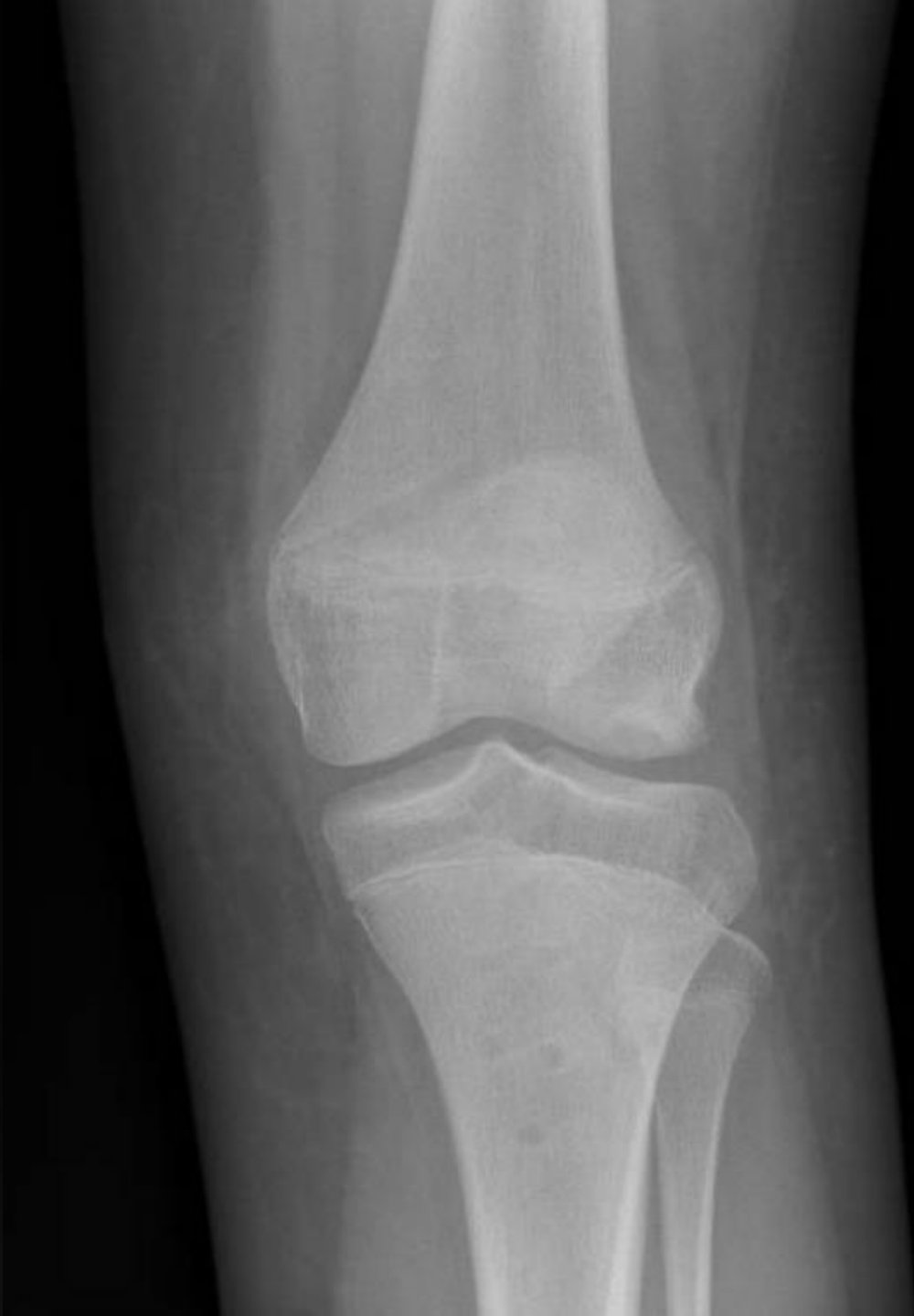
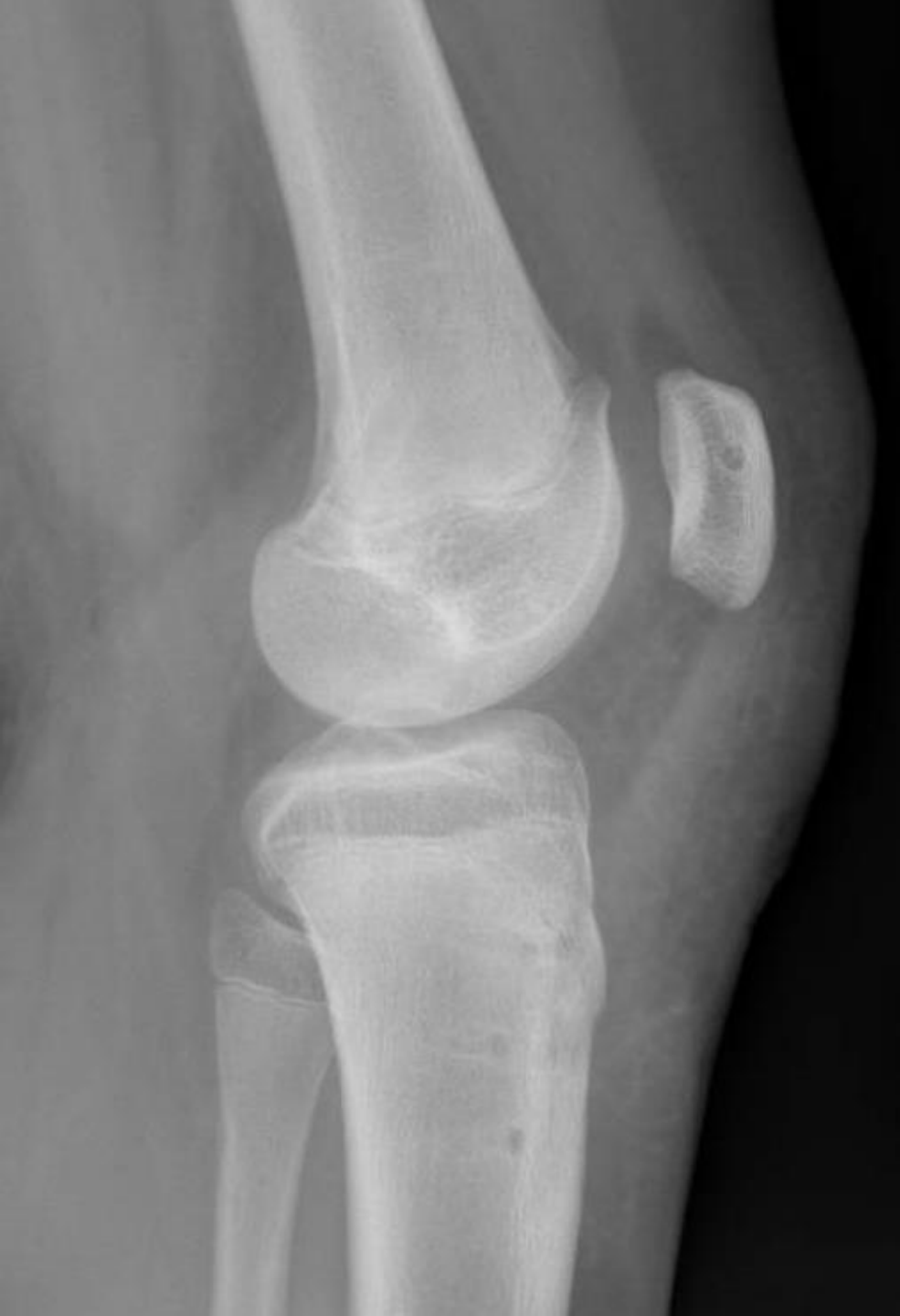
OR Right



OR Left





SUPINE

└
EK

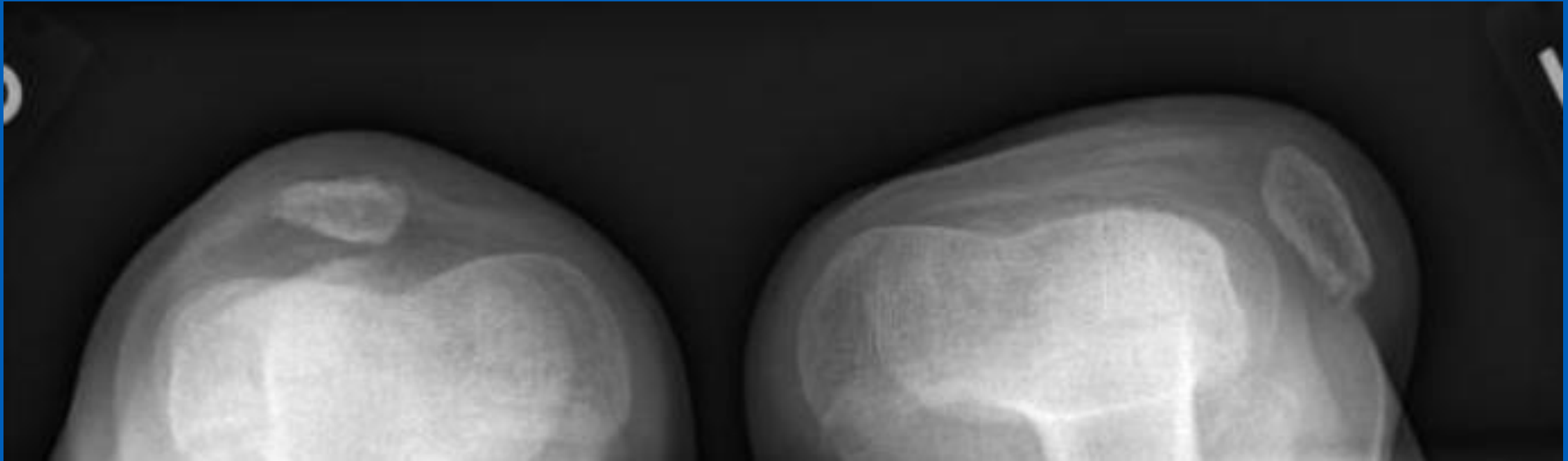


Case 3 12yo M

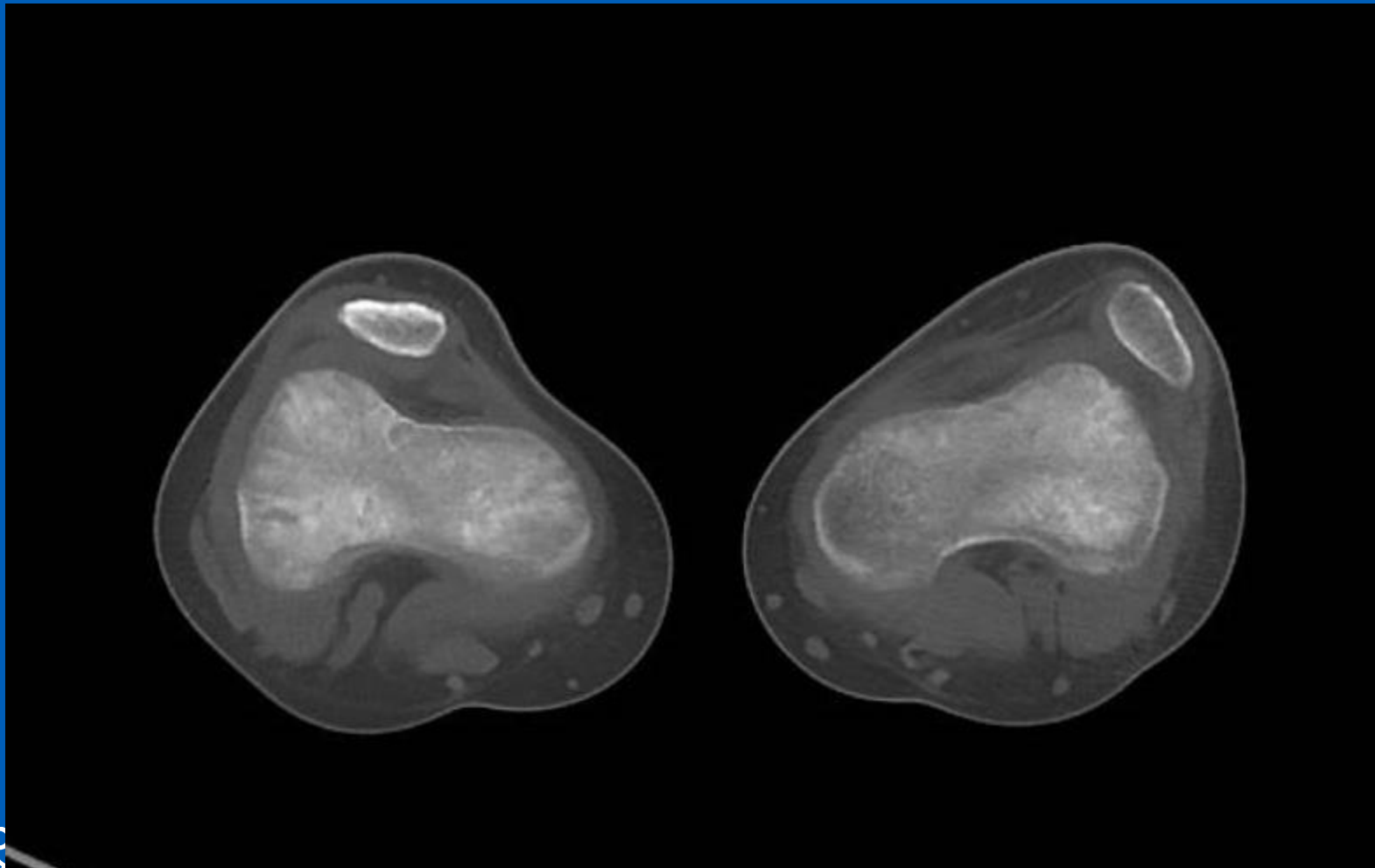
- Family history of Nail Patella Syndrome in dad
- Fixed lateral patella in extension that reduces in flexion
- PT and bracing made no difference on number of dislocations

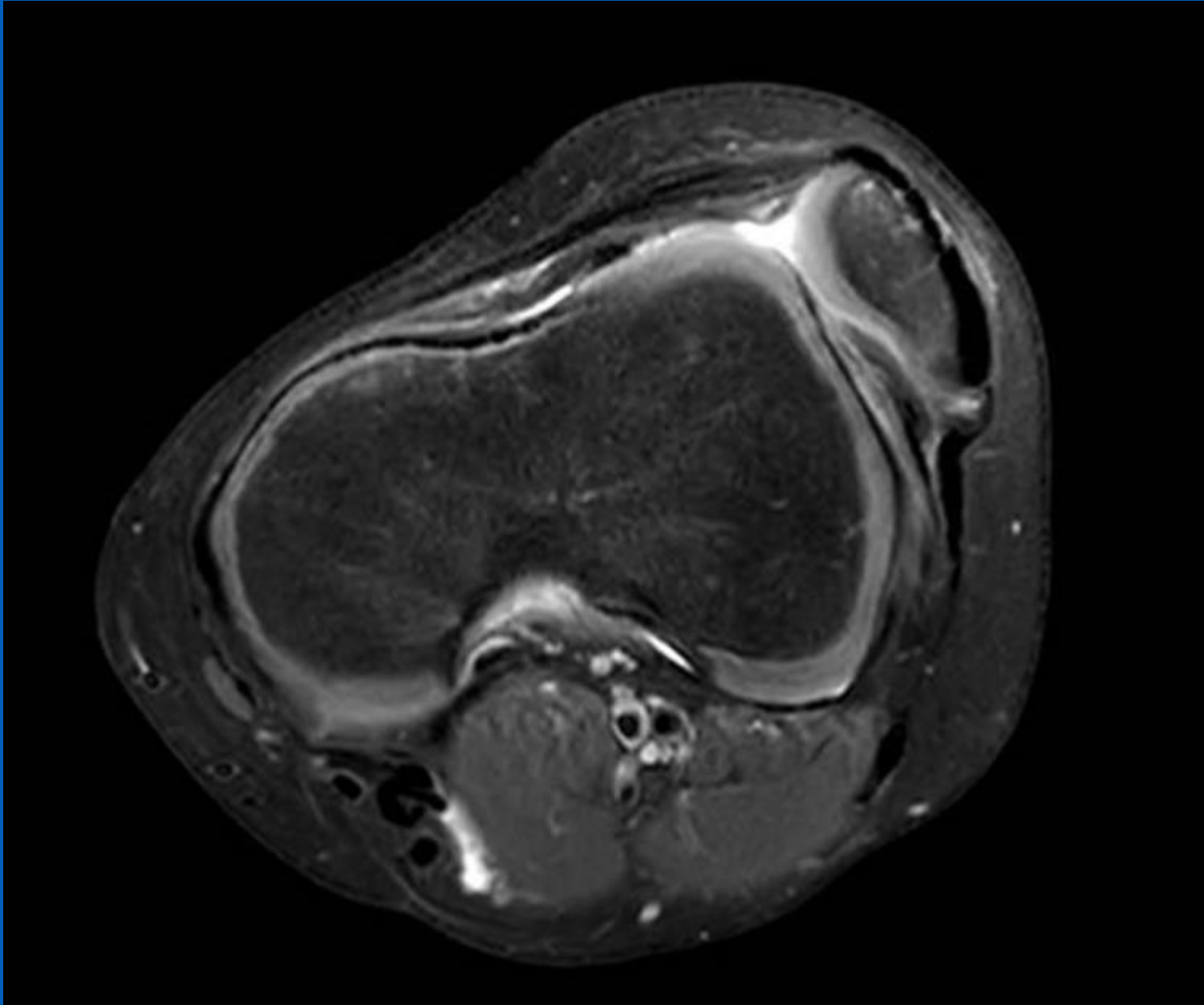


Xray



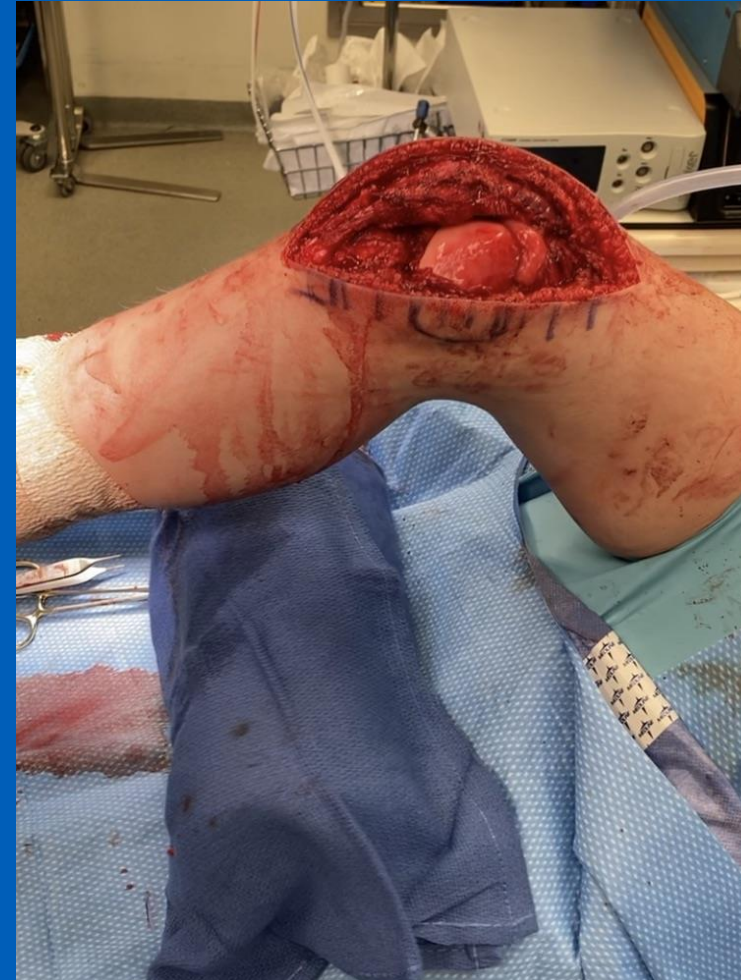CT





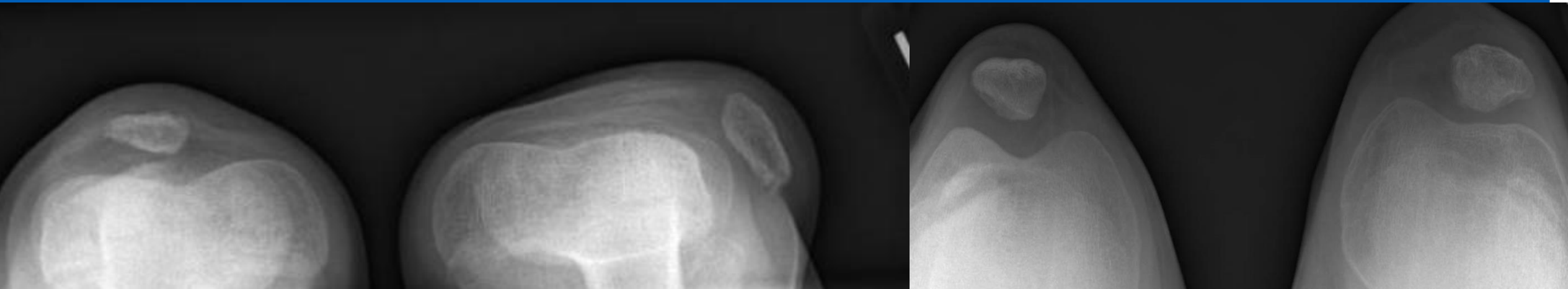OR

- Lateral release
- Quad tendon lengthening
- MPFL recon with quad autograft
- Distal patellar realignment
- Quadricepsplasty



1 Year Post OP

- ROM -5 to 150
- Full active extension
- No dislocations
- Asymmetric single leg squat with quad weakness
- Back to sports using J-brace



Summary

- Evaluate all the risk factors
- Tailor treatment to risk factors present
- Correct alignment first
- Keep a lot of tools in your treatment armamentarium



Thanks!

